



Emergency abdominal surgery

СИТНІК О.Л.

3MICT

Sytnik O. L., Leonov V.V., Petrenko V.Y.	8
SURGERY.	8
EMERGENCY ABDOMINAL	9
SURGERY.	9
Content	10
Introduction	10
Chapter 1 Acute appendicitis	11
Clinical diagnostic of acute appendicitis	12
Special examinations	15
Differential diagnosis of acute appendicitis	16
Treatment of acute appendicitis	17
Complications of acute appendicitis	18
Chapter 2 Acute cholecystitis	19
Clinical diagnostic of acute cholecystitis	20
Special examinations	21
Differential diagnosis of acute cholecystitis	22
Treatment of acute cholecystitis	23
Chapter 3 Acute pancreatitis	26
Etiology	26
Pathophysiology	27
Classifications	28
Savelyev V.S. (1983)	28
Atlanta's classification, Beger H.G., 1991	29
Clinical diagnostic of acute pancreatitis	29
Special examinations	30
Treatment of acute pancreatitis	32
Surgical care	33
Operations	33
Chapter 4 Perforated peptic ulcer	34
Etiology	34
Classifications	35
Clinical manifestations	36
Diagnosis programmer	37
Lab. Studies	37
Treatment of perforated peptic ulcer	38
Chapter 5 Peptic ulcer acute hemorrhage	39
Pathophysiology	40
Classifications	40
History	41
Clinical manifestation	41
Differential diagnosis	42

Diagnosis program	43
Lab studies	43
Imaging studies	44
Procedures	44
Tactic and choice of treatment method	44
Chapter 6 Bowel obstruction	46
A small-bowel obstruction (SBO)	47
Frequency	47
Pathophysiology	47
History	48
Physical	48
Lab Studies	49
Imaging studies	49
Treatment	51
Prognosis	51
Large bowel obstruction	51
History	52
Physical	52
Lab Studies	53
Imaging Studies	53
Procedures	54
Medical Care	54
Surgical Care	55
Further Outpatient Care	55
Prognosis	55
Pathophysiology	56
History	57
Lab studies	57
Imaging studies:	57
Medical Care	57
Chapter 7 Acute peritonitis	58
Relevant anatomy	58
Functions of peritoneum	59
Classifications	59
Pathophysiology	60
Clinical diagnostic of acute peritonitis	61
Lab. studies	62
Imaging studies	62
Medical therapy	63
Surgical treatment	64
Chapter 8 Hernias of abdominal wall	66
Etiology of hernias	67
Pathomorphology	67
Classification	67

Abdominal wall anatomy	68
Clinical sings	70
Inguinal herniorrhaphy. Alloplastic repair.	75
Femoral herniorrhaphy.	76
Umbilical and paraumbilical hernia	77
Postoperative hernia	78
Postoperative complications	79
TESTS FOR CONTROL	80
Chapter 1 Acute appendicitis	80
Standards of answers	82
Chapter 2 Acute cholecystitis	82
Standards of answers	84
Chapter 3 Acute pancreatitis	84
Standards of answers	86
Chapter 4 Perforated peptic ulcer	86
Standards of answers	87
Chapter 5 Peptic ulcer acute hemorrhage	87
Standards of answers	89
Chapter 6 Bowel obstruction	89
Standards of answers	91
Chapter 7 Acute peritonitis	92
Standards of answers	93
Chapter 8 Hernias of abdominal wall	94
Standards of answers	96
PROBLEMS	96
Standards of answers	96
Standards of answers	97
Standards of answers	98
Standards of answers	98
Standards of answers	99
Standards of answers	100
Standards of answers	100
Bibliography	101
Obligatory literature	101
Faculty literature	101
Additions	102
Addition A. Algorithm of diagnostic of acute appendicitis	102
Addition B. Algorithm of diagnostic and treatment of appendicular mass and abscess	103
Addition C. Algorithm of treatment of acute cholecystitis	104
Addition D. Algorithm of diagnosis and treatment of acute pancreatitis	105
Addition E. Algorithm of diagnosis and treatment of perforated ulcer	106

Addition F. Algorithm of diagnosis and treatment	107
of bleeding ulcer	107
of bowel obstruction	108
Addition K. Algorithm of treatment of hernias	109
Addition L. Algorithm of treatment of the	110
strangulated hernia	110
Subject index	111

- Sytnik O. L., Leonov V.V., Petrenko V.Y.
- SURGERY.
- EMERGENCY ABDOMINAL
- SURGERY.
- Content
- Introduction
- Chapter 1 Acute appendicitis
- Clinical diagnostic of acute appendicitis
- Special examinations
- Differential diagnosis of acute appendicitis
- Treatment of acute appendicitis
- Complications of acute appendicitis
- Chapter 2 Acute cholecystitis
- Clinical diagnostic of acute cholecystitis
- Special examinations
- Differential diagnosis of acute cholecystitis
- Treatment of acute cholecystitis
- Chapter 3 Acute pancreatitis
- Etiology
- Pathophysiology
- Classifications
- Savelyev V.S. (1983)
- Atlanta's classification, Beger H.G., 1991
- Clinical diagnostic of acute pancreatitis
- Special examinations
- Treatment of acute pancreatitis
- Surgical care
- Operations
- Chapter 4 Perforated peptic ulcer
- Etiology
- Classifications
- Clinical manifestations
- Diagnosis programmer
- Lab. Studies
- Treatment of perforated peptic ulcer
- Chapter 5 Peptic ulcer acute hemorrhage
- Pathophysiology
- Classifications
- History
- Clinical manifestation
- Differential diagnosis
- Diagnosis program
- Lab studies
- Imaging studies
- Procedures
- Tactic and choice of treatment method
- Chapter 6 Bowel obstruction
- A small-bowel obstruction (SBO)
- Frequency
- Pathophysiology
- History
- Physical
- Lab Studies
- Imaging studies
- Treatment
- Prognosis
- Large bowel obstruction
- History
- Physical
- Lab Studies
- Imaging Studies
- Procedures
- Medical Care

- Surgical Care
- Further Outpatient Care
- Prognosis
- Pathophysiology
- History
- Lab studies
- Imaging studies:
- Medical Care
- Chapter 7 Acute peritonitis
- Relevant anatomy
- Functions of peritoneum
- Classifications
- Pathophysiology
- Clinical diagnostic of acute peritonitis
- Lab. studies
- Imaging studies
- Medical therapy
- Surgical treatment
- Chapter 8 Hernias of abdominal wall
- Etiology of hernias
- Pathomorphology
- Classification
- Abdominal wall anatomy
- Clinical sings
- Inguinal herniorrhaphy. Alloplastic repair.
- Femoral herniorrhaphy.
- Umbilical and paraumbilical hernia
- Postoperative hernia
- Postoperative complications
- TESTS FOR CONTROL
- Chapter 1 Acute appendicitis
- Standards of answers
- Chapter 2 Acute cholecystitis
- Standards of answers
- Chapter 3 Acute pancreatitis
- Standards of answers
- Chapter 4 Perforated peptic ulcer
- Standards of answers
- Chapter 5 Peptic ulcer acute hemorrhage
- Standards of answers
- Chapter 6 Bowel obstruction
- Standards of answers
- Chapter 7 Acute peritonitis
- Standards of answers
- Chapter 8 Hernias of abdominal wall
- Standards of answers
- PROBLEMS
- Standards of answers
- Standards of answers
- Standards of answers
- Standards of answers
- Standards of answers
- Standards of answers
- Standards of answers
- Standards of answers
- Bibliography
- Obligatory literature
- Faculty literature
- Additions
- Addition A. Algorithm of diagnostic of acute appendicitis
- Addition B. Algorithm of diagnostic and treatment of appendicular mass and abscess
- Addition C. Algorithm of treatment of acute cholecystitis
- Addition D. Algorithm of diagnosis and treatment of acute pancreatitis
- Addition E. Algorithm of diagnosis and treatment

- of perforated ulcer
- Addition F. Algorithm of diagnosis and treatment
- of bleeding ulcer
- of bowel obstruction
- Addition K. Algorithm of treatment of hernias
- Addition L. Algorithm of treatment of the
- strangulated hernia
- Subject index

MINISTRY OF PUBLIC HEALTH OF UKRAINE
MINISTRY OF EDUCATION AND SCIENCE OF UKRAINE
SUMY STATE UNIVERSITY



**Sytnik O. L., Leonov V.V.,
Petrenko V.Y.**

SURGERY.

EMERGENCY ABDOMINAL

SURGERY.

TUTORIAL

SUMY
2011

Рецензенти:

чл.-кор. АМН України, д. мед. н., проф. В.І. Лупальцов
(Харківський національний медичний університет);
д. мед. н., проф. О.В. Лігоненко
(Полтавська стоматологічна академія);
д. мед. н., проф. Ю.Л. Шальков
(Харківська медична академія післядипломної освіти)

Ситнік О.Л., Леонов В.В., Петренко В.Ю.

“Surgery. Emergency abdominal surgery”. Навчальний посібник. - 2011. - 189с.

Посібник містить інформацію про етіологію, патогенез, загальні принципи діагностики та лікування гострих хірургічних захворювань органів черевної порожнини, що відповідає новій навчальній програмі з хірургії для студентів вищих медичних навчальних закладів III-IV рівнів акредитації (Київ, 2008). Акцентовано увагу на сучасні методики діагностики та хірургічного лікування гострих хірургічних захворювань органів черевної порожнини.

Tutorial contains information about etiology, pathogenesis, general diagnostic and treatment approaches for acute surgical abdominal pathology in accordance with new training program “Surgery” for students of higher educational establishments of the III - IV levels (Kiev, 2008). Information emphases are modern diagnostic and treatment techniques in emergency abdominal surgery.

□□О.Л.Ситнік, В.В.Леонв 2011

Content

Page	
Introduction	4
Chapter 1 Acute appendicitis	5
Chapter 2 Acute cholecystitis	23
Chapter 3 Acute pancreatitis	35
Chapter 4 Perforated peptic ulcer	50
Chapter 5 Peptic ulcer acute hemorrhage	60
Chapter 6 Bowel obstruction	74
Chapter 7 Acute peritonitis	92
Chapter 8 Hernias of abdominal wall	110
Tests for control	138
Problems	165
Bibliography	173
Additions	176
Subject index	186

Introduction

The publication of this tutorial is caused by the conversion to the credit - modular training system in concordance with new training program "Surgery" for students of higher educational establishments of the III - IV levels (Kiev, 2008).

Surgery, especially emergency surgery, is very important for all physicians. It starts at the IV-th academic year after finishing fundamental disciplines such as pathologic anatomy, pathologic physiology, pharmacology, topographic anatomy, operative surgery and initial clinical disciplines: general surgery, propaedeutics of internal diseases. Surgery forms the basic knowledge for successful study of the special branches of internal diseases.

The general purpose is: assimilation of theoretical and practical knowledges about etiology, pathogenesis, typical clinical manifestations, and methods of diagnosing, conservative treatment, operative treatment, rehabilitation of acute surgical diseases for general practice physicians.

Concrete purposes are:

- interpretation of etiology, pathogenesis, classifications, typical clinical manifestations of the most

frequent acute surgical diseases;

- formation of algorithms of diagnosing, conservative and operative treatment, postoperative treatment and rehabilitation;
- differential diagnostics of acute diseases of abdominal cavity, retroperitoneal space and chest cavity;
- evaluation of the results of lab. tests and additional methods of investigations in patients with surgical abdominal pathology;
- identification of the indications for laparoscopic and paracentetic (under ultrasound or CT-scan control) techniques.

Chapter 1 Acute appendicitis

Acute appendicitis is nonspecific inflammation of the inner lining of the vermiform appendix that spreads to its other parts. Appendicitis is the most common acute surgical emergency of the abdomen. The incidence of acute appendicitis is around 7% of the population in the United States and in European countries. In Asian and African countries, the incidence is probably lower because of the dietary habits. Appendicitis occurs more frequently in males than in females, with a male-to-female ratio of 1,7:1.

From without inwards the structure of appendix is as follows:

1. 1. Serous coat is composed of peritoneal coat, which covers the whole of the appendix except along the narrow line of attachment of the mesoappendix.
2. 2. Muscle coat. It consists of outer longitudinal muscles and inner circular muscles as seen in case of small intestine. The longitudinal muscle is formed by coalescence of the three taeniae coli at the junction of the caecum and appendix. Thus the taeniae, particularly the anterior taenia may be used as a guide to locate an elusive appendix. The inner circular muscle is continuation of the same muscle in the caecum. The peculiarity of the musculature of the appendix is that there are a few gaps in the muscular layer called "hiatus muscularis". Through this infection from the submucous coat directly comes to peritoneum and regional peritonitis occurs.
3. 3. Submucosal coat. The submucous coat of the appendix is very rich in lymphoid tissue. It contains lymphoid follicles which are known as "abdominal tonsil".
4. The mucous coat resembles that of large intestine.

Various anatomical positions of appendix are:

1. Retrocaecal position (commonest irregular position -70%) - the appendix lies behind the caecum although in majority of cases in an intraperitoneal location. Only in case of long retrocaecal appendix the tip of the appendix remains in the retroperitoneal tissue close to the ureter.

1. Pelvic position (second most common irregular position - 25%).
2. Subcaecal (2%).
3. Subhepatic (3 %) - that means the tip of the appendix is towards the liver.

Etiology of acute appendicitis:

1. Obstruction of the lumen of the appendix (fecoliths, hyperplasia of submucosal lymphoid follicle, intestinal worms vegetables, fruit seeds, barium from previous X-rays).
2. The bacteriology flora. Most frequently seen organisms are Esch. coli, enterococci, bacteroides (gram-negative rod), nonhaemolytic streptococci, anaerobic streptococci and Cl. Welchii.
3. 3. Diet which is relatively rich with fish and meat.

Appendicitis usually has 3 stages:

- Edematous stage. Appendicitis may have spontaneous regression or may evolve to the second stage. The mesoappendix is commonly involved with inflammation.
- Purulent (phlegmonous) stage. Spontaneous regression rarely occurs. Appendicitis usually evolves beyond perforation. Peritonitis may be possible.

- Gangrenous stage. Spontaneous regression never occurs.

Kolesov's classification of acute appendicitis (1952):

1. Appendicular colic.
2. Simple superficial appendicitis.
3. Destructive appendicitis:
 - a) phlegmonous;
 - b) gangrenous;
 - c) perforated.
4. Complicated appendicitis:
 - a) appendicular mass;
 - b) appendicular abscess;
 - c) diffuse purulent peritonitis.
5. Other complications of acute appendicitis (pylephlebitis, sepsis, retroperitoneal phlegmon, local abscesses of abdominal cavity).

Clinical diagnostic of acute appendicitis

The disease begins with a sudden pain in the abdomen. It is localized in a right iliac area, has moderate intensity, constant character and not irradiate. With 70 % of patients the pain arises in epigastric area or other part of abdominal cavity - it is an "epigastric phase" of acute appendicitis. In 2-4 hours it moves to the place of appendix existence (the *Kocher's sing*). At coughing patients mark strengthening of pain in a right iliac area - it is a positive cough symptom.

Together with it, nausea and vomiting that have reflex character can disturb a patient. The temperature of body of most patients rises, but it is a low grade fever. The general condition of patients is usually normal and gets worse only in case of growth of destructive changes in appendix.

Painfulness is the basic and decisive signs of acute appendicitis during the examination by palpation in a right iliac area. Tension of muscle of abdominal wall is a positive symptom of peritoneum irritation.

The Blumberg's sing. After gradual pressing by fingers on a front abdominal wall from the place of pain quickly, but not acutely, the hand is taken away. Strengthening of pain is considered as a positive symptom in that place. Obligatory here is tension of muscles of front abdominal wall.

The Voskresensky's sing. By a left hand the shirt of patient is drawn downward and fixed on pubis. By the taps of 2-4 fingers of right hand epigastric area is pressed and during exhalation of patient quickly and evenly the hand slides in the direction of right iliac area, without taking the hand away. Thus there is an acute strengthening of pain.

1. *The Rovsing's sing (fig 1).* By a left hand a sigmoid bowel is pressed to the back wall of stomach. By a right hand by balloting palpation a descending bowel is pressed. Appearance of pain in a right iliac area is considered as a sign characteristic of appendicitis.
2. *The Sitkovsky's sing (fig 2).* A patient, that lies on left, feels the pain which arises or increases in a right iliac area. The mechanism of intensification of pain is explained by displacement of blind gut to the left, by drawing of mesentery of the inflamed appendix.
3. *The Obrazcov's sing (fig 3).* With the position of patient on the back by index and middle fingers the right iliac area of most painful place is pressed and the patient is asked to heave up the straightened right leg. At appendicitis pain increases acutely.
4. *The Bartomier's sing (fig 4)* is the increase of pain intensity during the palpation in right iliac area of patient in position on the left side. At such pose an omentum and loops of small intestine is displaced to the left, and an appendix becomes accessible for palpation.

The Rozdolsky's sing. At percussion there is painfulness in a right iliac area.

The psoas (Rovsing's) sign. This test is performed by having the patient lie on his left side. The examiner slowly extends the patient's right thigh, thus stretching the ileopsoas muscle. This will produce pain to make the sign positive. This indicates presence of irritative inflamed appendix in close proximity to the psoas muscle. This is possible in retrocaecal appendicitis.

Acute appendicitis in children. With children of infancy acute appendicitis can be seen infrequently, but, quite often carries atypical character. All this is conditioned, mainly, by the features of anatomy of appendix, insufficient of plastic

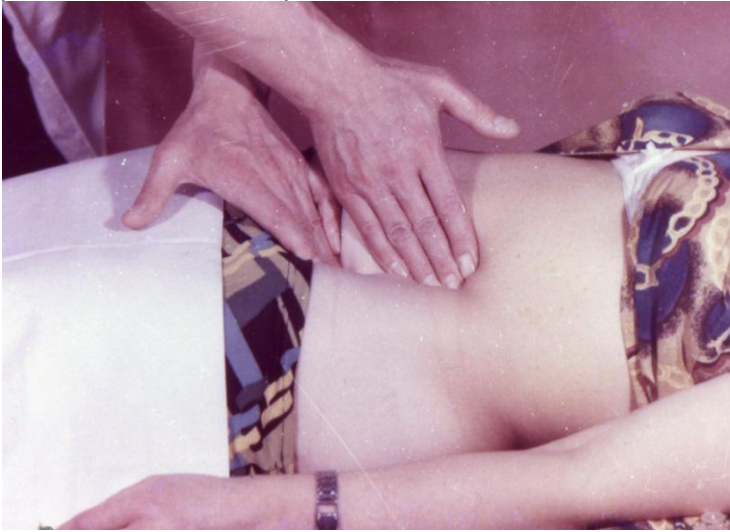

Figure 1. Detection of Rovsing's sign

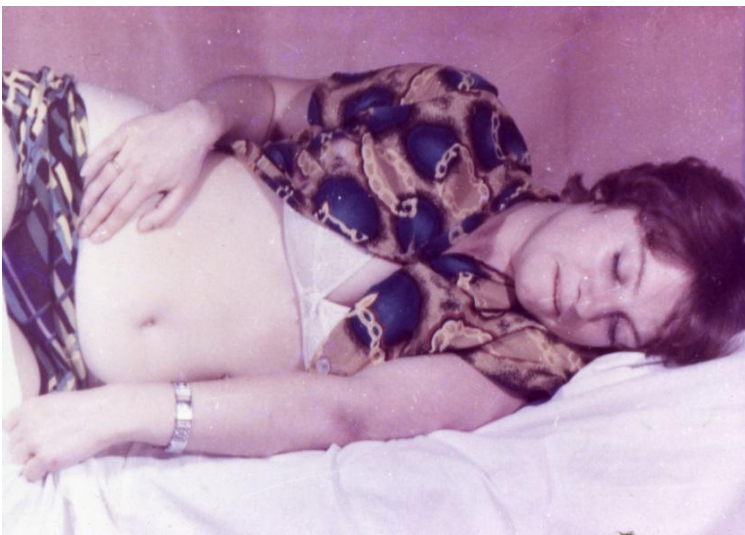

Figure 2. Detection of Sitkovsky's sign

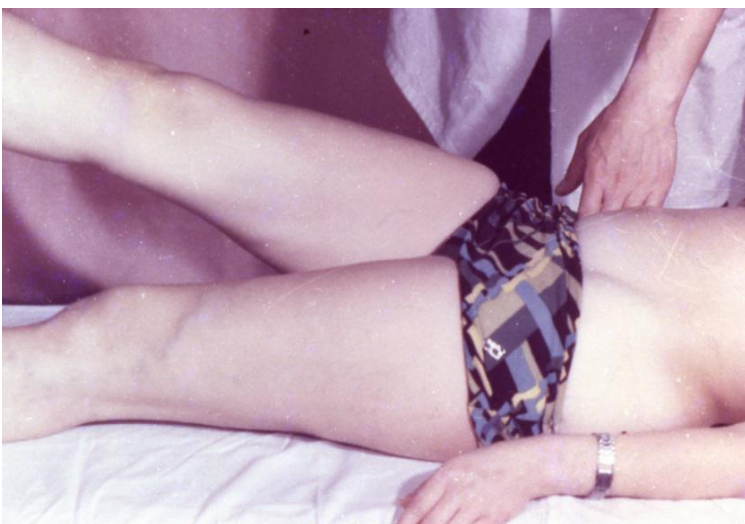


Figure 3. Detection of Obrazcov's sign

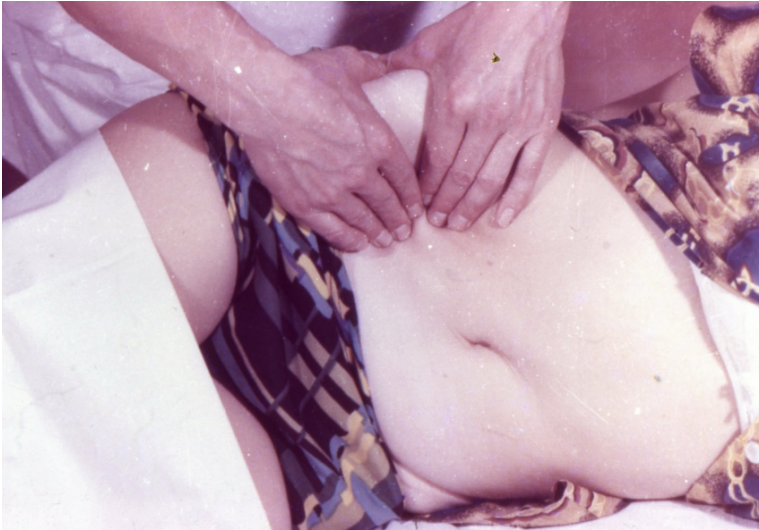

Figure 4. Detection of Bartomier's sign

properties of the peritoneum, short omentum and high reactivity of child's organism. The inflammatory process in the appendix of children quickly makes progress and during the first half of days from the beginning of disease there can appear its destruction, even perforation. The child, more frequent than an adult, suffers vomiting. Its general condition gets worse quickly, and already the positive symptoms of irritation of peritoneum can show up during the first hours of a disease. The temperature reaction is also expressed considerably acuter. In the blood test there is high leukocytosis.

Acute appendicitis of the people of declining and old ages can be met not so often, as of the persons of middle ages and youth. This contingent of patients is hospitalized to hospital rather late: in 2-3 days from the beginning of a disease. Because of the promoted threshold of pain sensitiveness, the intensity of pain in such patients is small, therefore they almost do not fix attention on the epigastric phase of appendicitis. More frequent are nausea and vomiting, and the temperature reaction is expressed poorly. Tension of muscles of abdominal wall is absent or insignificant through old-age relaxation of muscles. But the symptoms of irritation of peritoneum keep the diagnostic value with this group of patients. Thus, the sclerosis of vessels of appendix results in its rapid numbness, initially-gangrenous appendicitis develops. Because of such reasons the destructive forms of appendicitis prevail, often there is appendicular infiltrate.

With pregnant women both the bend of appendix and violation of its blood flow are causes of the origin of appendicitis. Increased in sizes uterus causes such changes. It, especially in the second half of pregnancy, displaces a blind gut together with an appendix upwards, and an overdistension abdominal wall does not create adequate tension. Together with that, psoas-sign and the Kocher's sign, Bartomier's sign have a diagnostic value at pregnant women.

Appendicitis at retrocecal and retroperitoneal location. Thus an appendix can be placed both in a free abdominal cavity and retroperitoneal. An atypical clinic arises, as a rule, at the retroperitoneal location. The patients complain at pain in lumbus or above the wing of right ileum. There they mark painfulness during palpation. Sometimes the pain irradiates to the pelvis and in the right thigh. The positive *Rozanov's sign* - painfulness during palpation in the right Pti triangle is characteristic. In transition of inflammatory process on an ureter and kidney in the urines analysis red corpuscles can be found.

The pelvic location of appendix. In such patients the pain is localized above the right Poupert's ligament and above pubis. At the very low placing of appendix at the beginning of disease the reaction of muscles of front abdominal wall on an inflammatory process can be absent. With transition of inflammation of an urinary bladder or rectum either the dysuric signs or diarrhea develop. Distribution of process on internal genital organs provokes signs characteristic of their inflammation.

Appendicitis at the medial placing of appendix. The appendix in patients with such pathology is located between the loops of intestine, which is the large field of irritation of peritoneum. At these anatomic features mesentery is pulled in the inflammatory process, acute dynamic of the intestinal obstruction develops in such patients. The pain in the abdomen is intensive, widespread, the expressed tension of muscles of abdominal wall develops.

For the subhepatic location of appendix the pain is characteristic in right hypochondrium. During palpation painfulness and tension of muscles can be marked.

Left-side appendicitis appears infrequently and, as a rule, in case of the reverse placing of all organs; however it can occur at a mobile blind gut. In this situation all signs which characterize acute appendicitis will be exposed not on the right, as usually, but on the left.

Special examinations

White Blood Cell Count. The white blood cell count in the blood usually becomes elevated with infection. Unfortunately, appendicitis is not the only condition that causes elevated white blood cell counts. Almost any infection or inflammation can cause this count to be abnormally high. Therefore, an elevated white blood cell count alone cannot be used as a sign of appendicitis.

Urinalysis. Urinalysis is a microscopic examination of the urine that detects red blood cells, white blood cells and bacteria in the urine. Urinalysis usually is abnormal when there is inflammation or stones in the kidneys or bladder. The urinalysis also may be abnormal with appendicitis because the appendix lies near the ureter and bladder. If the inflammation of appendicitis is great enough, it can spread to the ureter and bladder leading to an abnormal urinalysis. Most patients with appendicitis, however, have a normal urinalysis. Therefore, a normal urinalysis suggests appendicitis more than a urinary tract problem.

Abdominal X-Ray. An abdominal X-ray may detect the fecalith that may be the cause of appendicitis. This is especially true in children.

Chest films may be performed to exclude any disease of the base of the right lung as disease in this area may irritate the spinal nerve to simulate the symptoms of appendicitis.

Ultrasound (US). Ultrasound can identify an enlarged appendix or an abscess. Nevertheless, during appendicitis, the appendix can be seen in only 50% of patients. Therefore, not seeing the appendix during an ultrasound does not exclude appendicitis. Ultrasound also is helpful in patients with renal colic and in women because it can exclude the presence of conditions involving the ovaries, fallopian tubes and uterus.

Ultrasound target sign of acute appendicitis can be detected (fig. 5). Transverse ultrasound scan through an inflamed appendix shows an intact echogenic submucosal layer and a fluid-filled lumen (F), resulting in a "target" appearance.

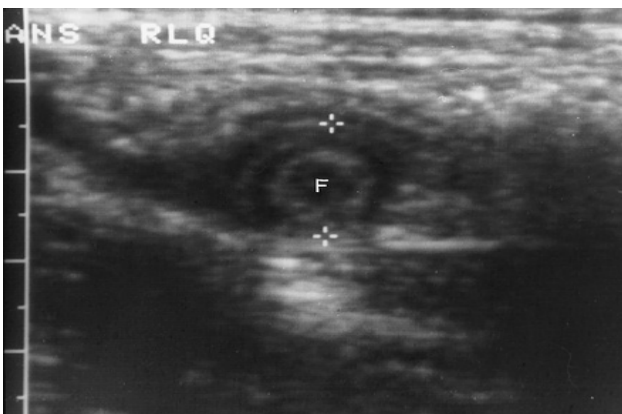


Figure 5. Acute appendicitis with target sign.

Computerized tomography (CT) scan. In patients who are not pregnant, a CT scan of the area of the appendix is useful in diagnosing appendicitis and periappendicular abscesses (fig. 6) as well as in excluding other diseases inside the abdomen and pelvis that can mimic appendicitis.

Laparoscopy. Laparoscopy is a surgical procedure in which a small fiber optic tube with a camera is inserted into the abdomen through a small puncture made on the abdominal wall. Laparoscopy allows a direct view of the appendix as well as other abdominal and pelvic organs. If appendicitis is found, the inflamed appendix can be removed with the laparoscope.

Differential diagnosis of acute appendicitis

Food toxicoinfection. Complaints for pain in the epigastric area of the intermittent character, nausea, vomiting and liquid emptying are the first signs of disease. The state of

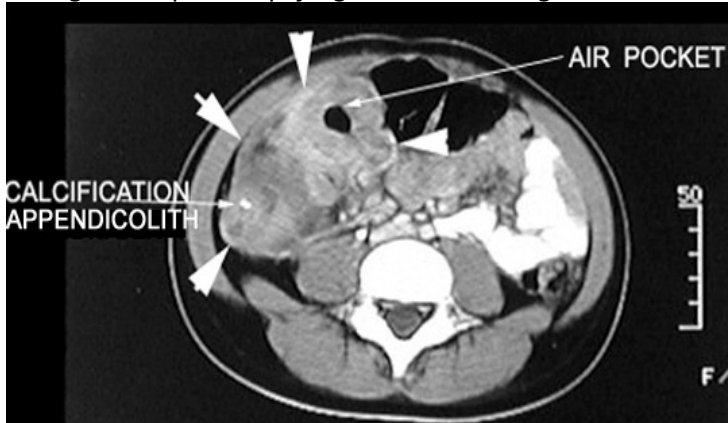


Figure 6. Acute appendicitis with periappendicular abscesses

patients progressively gets worse from the beginning. Next to that, it is succeeded to expose that a patient used meal of poor

quality. However, here patients do not have phase passing, which is characteristic of acute appendicitis, and clear localization of pain. Defining the symptoms of irritation of peritoneum are not succeeded, the peristalsis of intestine is increased.

Acute pancreatitis. In anamnesis in patients with this pathology there is a gallstone disease, violation of diet and use of alcohol. Their condition from the beginning of a disease is heavy. Pain is considerably more intensive, than during appendicitis, and is concentrated in the upper half of abdomen. Vomiting is frequent and does not bring to the recovery of patients.

Acute cholecystitis. The high placing of vermiform appendix in the right half of abdomen during its inflammation can cause the clinic somewhat similar to acute cholecystitis. But unlike appendicitis, in patients with cholecystitis the pain is more intensive, has cramp-like character, is localized in right hypochondrium and irradiate in the right shoulder. Also the epigastric phase is absent. The attack of pain can arise after the reception of spicy food and, is accompanied by nausea and frequent vomiting by bile. In anamnesis patients often have information about a gallstone disease. During examination intensive painfulness is observed in right hypochondrium, increased gallbladder and positive *Murphy's* and *Ortner's* sings.

Perforated peptic ulcer. Diagnostic difficulties during this pathology arise up only on occasion. They can be in patients with the covered perforation, when portion of gastric juice flows out in an abdominal cavity and stays too long in the right iliac area, or in case of atypical perforations. On the abdominal X-ray gram under the right copula of diaphragm free gaze can be found.

The apoplexy of ovarya more frequent is with young women and, as a rule, on 10-14 day after menstruation. Pain appears suddenly and irradiate in the thigh and perineum. At the beginning of disease there can be a collapse. However, the general condition of patients suffers insignificantly. When not enough blood was passed in the abdominal cavity, all signs of pathology of abdominal cavity organs calm down after some time. Signs, which are characteristic of acute anemia, appear at considerable hemorrhage. Abdomen more frequent is soft and painful down, (positive *Kulenkamppf's sing*: acute pain during palpation of stomach and absent tension of muscles of the front abdominal wall).

Extra-uterine pregnancy. A necessity to differentiate acute appendicitis with the interrupted extra-uterine pregnancy arises, when during the examination the patient complains at the pain only down in the stomach, more to the right. Taking it into account, it is needed to remember, that at extra-uterine pregnancy a few days before there can be intermittent pain in the lower part of the abdomen, sometimes excretions of "coffee" color appear from vagina. In anamnesis often there are the present gynecological diseases, abortions and pathological passing of pregnancy. For the clinical picture of such patient inherent sudden appearance of intensive pain in lower part of the abdomen. Often there is a brief loss of

consciousness. During palpation considerable painfulness is localized lower, than at appendicitis, the abdomen is soft, the positive *Kulenkampff's* sign is determined. Violations of menstrual cycle testify for pregnancy, characteristic changes are in milk glands, vagina and uterus. During the vaginal examination it is sometimes possible to palpate increased tube of uterus. The temperature of body more frequently is normal. If hemorrhage is small, the changes in the blood test are not present. The convincing proof of the broken extra-uterine pregnancy is the dark color of blood, taken at puncture of back fornix of vagina.

Right-side kidney colic. For this disease pain at the level of kidney and in lumbus is inherent, hematuria and dysuric signs which can take place at the irritation of ureter by the inflamed appendix. Intensity of pain in kidney colic is one of the basic differences from acute appendicitis. Pain at first appears in lumbus and irradiate downward after passing of ureter in genital organs and front surface of the thigh. In diagnostics urogram survey is important, and if necessary – chromocystoscopy. Absence of function of right kidney to some extent allows eliminating the diagnosis of acute appendicitis.

Diabetic abdomen — indicates abdominal pain and vomiting which precede coma.

Treatment of acute appendicitis

Acute appendicitis is treated by surgery to remove the appendix (appendectomy). The operation may be performed through a standard small incision in the right lower part of the abdomen, or it may be performed using a laparoscopy, which requires three to four smaller incisions. In patients with diffuse or general peritonitis middle line laparotomy is preferred.

Do not administer analgesics and antipyretics to patients with suspected appendicitis who have not been evaluated by the surgeon.

Preparation of patients undergoing appendectomy is similar for both open and laparoscopic procedures. Perform complete routine laboratory and radiologic studies before intervention. Venous access must be obtained in all patients diagnosed with appendicitis. Venous access allows administration of isotonic fluids and broad-spectrum intravenous antibiotics prior to the operation. Prior to the start of the surgical procedure, the anesthesiologist performs endotracheal intubation to administer volatile anesthetics and to assist respiration. The abdomen is washed, antiseptically prepared, and then draped.

Open appendectomy

Surgical incisions for open appendectomy are:

- line oblique incision over the McBurney point (i.e., two thirds of the way between the umbilicus and the anterior superior iliac spine);
- vertical incisions (i.e., the Battle pararectal) are rarely performed because of the tendency for herniation;
- middle line laparotomy.

After cutting of peritoneum abdominal cavity is opened. Note the character of any peritoneal fluid to help confirm the diagnosis and then suction it from the field. If it is purulent, collect and culture the fluid.

The convergence of taenia coli is detected at the base of the appendix, beneath the Bauhin valve (i.e., the ileocaecal valve), and the appendix is then viewed. If the appendix is hidden, it can be detected medially by retracting the caecum and laterally by extending the peritoneal incision.

After exteriorization of the appendix, the mesoappendix is held between clamps, divided, and ligated. The appendix is clamped proximally about 5 mm above the caecum to avoid contamination of the peritoneal cavity and is cut above the clamp by a scalpel. The appendix must be ligated to prevent bleeding and leakage from the lumen. The appendix may be inverted into the caecum with the use of a pursestring suture or z-stitch.

The caecum is placed back into the abdomen. The abdomen is irrigated. When evidence of free perforation exists, peritoneal lavage with several liters of warm saline is recommended. After the lavage, the irrigation fluid must be completely aspirated to avoid the possibility of spreading infection to other areas of the peritoneal cavity. The use of a drain is not commonly required in patients with acute appendicitis, but obvious abscess with gross contamination requires drainage.

The wound closure begins by closing the peritoneum with a running suture. Then, the fibers of the muscular and fascial layers are reapproximated and closed with a continuous or interrupted absorbable suture. Lastly, the skin is closed with subcutaneous sutures or staples. In cases of perforated

appendicitis, some surgeons leave the wound open, allowing for secondary closure or a delayed primary closure until the fourth or fifth day after operation. Other surgeons prefer immediate closure in these cases.

Laparoscopic appendectomy

According to the preferences of the surgeon, a short supraumbilical incision is made to allow the placement of a Hasson cannula or Veress needle. Pneumoperitoneum (10-14 mm Hg) is established and maintained by insufflating carbon dioxide. Through the access, a laparoscope is inserted to view the entire abdomen cavity. A 10-mm port is inserted through supraumbilical incision for camera. Another two 5-mm ports are placed in the right and left inguinal regions for manipulations. The appendix is grasped and retracted upward to expose the mesoappendix. The mesoappendix is divided, ligated or coagulated. The appendix may be transected with a linear Endostapler, or, alternately, the base of the appendix may be suture ligated in a usual manner to that in an open procedure. The appendix is removed using a laparoscopic pouch to prevent wound contamination.

Postoperative treatment

Administer intravenous antibiotics postoperatively. The length of administration is based on the operative findings and the recovery of the patient. In complicated appendicitis, antibiotics may be required for many days or weeks.

Antiemetic's and analgesics are administered to patients experiencing nausea and wound pain. The patient is encouraged to ambulate early.

In patients with complicated appendicitis, a clear liquid diet may be started when bowel function returns.

Follow-up care

After hospital discharge, patients must have a light diet and limit their physical activity for a period of 2-6 weeks based on the surgical approach (i.e., laparoscopic or open appendectomy). The patient should be evaluated by the surgeon in the clinic to determine improvement and to detect any possible complications:

- wound infection especially in patients with gangrenous or perforated appendicitis;
- ileus;
- caecal fistulas;
- pelvic or abdominal abscess.

Complications of acute appendicitis

Appendicular mass. In majority of cases as soon as the appendix becomes gangrenous, omentum and coils of small intestine cover the appendix all around. There is no discrete collection of pus inside. This is an attempt of the nature to prevent general peritonitis even if rupture of the appendix occurs. Usually such appendicular mass develops on die 3rd day after the commencement of an attack of acute appendicitis. This is a tender mass on the right iliac fossa. This mass usually resolves by conservative treatment. In untreated cases of when the patient does not react to the conservative treatment such appendicular mass may turn into an appendicular abscess and becomes larger in size.

Treatment of the appendicular mass. In these cases conservative treatment should be started immediately. Nature has already localized, the lesion and it is better not to disturb such localization. Surgery at this stage is difficult and dangerous as it is difficult to find appendix due to adhesions and ultimately fecal fistula may form.

Conservative treatment includes intravenous fluid with dextrose saline and Ringer solution as and when required; nasogastric aspiration; antibiotic therapy. A broad spectrum antibiotic should be given intramuscularly. Metronidazole may be given intravenously.

The conditions for stopping the conservative treatment are: a) arising pulse rate; b) vomiting or increase in gastric aspiration; c) increasing abdominal pain - suggesting spreading peritonitis; d)

increasing of the size of the mass.

About 90% of cases resolve without any problem. The patient is kept under observation for further 4 to 5 days after resolution of the mass. Patient is instructed to have appendectomy done 6 to 8 weeks after his discharge.

Appendicular abscess. A progressive supportive process in an appendicular mass forms an appendicular abscess walled off by the omentum, inflamed caecum and coils of small intestine. Such abscess may follow rupture of the appendix. The most common site of the abscess is in the lateral part of the iliac fossa (from retrocaecal appendicitis). The second common position is in the pelvis. In untreated cases lethal form of peritonitis is produced by secondary rupture of appendicular abscess.

At abscessing of infiltrate the condition of a patient gets worse, the symptoms of acute appendicitis become more expressed, the temperature of body, which in most cases gains hectic character, rises, the fever appears. Next to that, pain in the right iliac area increases. Painful formation is felt there. In the blood test high leukocytosis is present with the acutely expressed change of leukocyte formula to the left. The temperature of body rises to 38,0–39,0°C. During the rectal examination the weakened sphincter of anus is found. The front wall of rectum at first is only painful, and then its overhanging is observed as dense painful infiltrate.

Treatment of appendicular abscess. Immediate drainage under antibiotic cover is the treatment of choice. Appendectomy is not performed. A pelvic abscess may be drained in the female into the vagina and in the male into the rectum. If the appendix is not removed when the abscess is drained, interval of appendectomy should be done 6 to 8 weeks after.

Pylephlebitis. Ascending septic thrombophlebitis of portal venous system (pylethrombophlebitis) is a grave but rare complication of gangrenous appendicitis. Septic clots from involved mesenteric veins produce multiple pyogenic abscesses in the liver. It is more frequent in patients with acute retrocaecal appendicitis. It is heralded by chills, spiking fever, right upper quadrant pain and jaundice. Pylephlebitis is a complication of both appendicitis and after-operative period of appendectomy.

In case with rapid passing of disease the icterus appears, the liver is increased, kidney-hepatic insufficiency makes progress, and patients die in 7-10 days from the beginning of disease.

At gradual subacute development of pathology the liver and spleen is increased in size, and after the septic state of organism ascites arises.

Peritonitis. Peritonitis is happened when bacterial and other contents of the appendix leak into the abdomen.

Chapter 2 Acute cholecystitis

Acute cholecystitis is nonspecific inflammation of gallbladder. After frequency this disease takes second place after acute appendicitis and makes about 10 % in relation to all acute surgical diseases of organs of abdominal cavity.

Acute cholecystitis occurs most commonly because of an obstruction of the cystic duct from cholelithiasis. Ninety percent of cases involve stones in the cystic duct (i.e., calculous cholecystitis), with the other 10% representing acalculous cholecystitis.

Acalculous acute cholecystitis is related to conditions associated with biliary stasis, including debilitation, major surgery, severe trauma, sepsis, long-term total parenteral nutrition and prolonged fasting. Other causes of acalculous cholecystitis include cardiovascular events; sickle cell disease; Salmonella infections; diabetes mellitus; and cytomegalovirus, cryptosporidiosis or microsporidiosis infections in patients with AIDS.

Although bile cultures are positive for bacteria in 50-75% of cases, bacterial proliferation may be a result of cholecystitis and not the precipitating factor.

Risk factors for cholecystitis include increasing age, female sex, certain ethnic groups, obesity or rapid weight loss, drugs and pregnancy.

As a result inflammatory process develops from simple (catarrhal or superficial) cholecystitis till

destructive cholecystitis (phlegmonous, gangrenous) and complicated cholecystitis.

Classification. Acute cholecystitis is divided into:

- I. Acute calculous cholecystitis.
- II. Acute non-calculous cholecystitis.

1. Catarrhal.
2. Phlegmonous.
3. Gangrenous.
4. Complicated:

- a) hydropsy;
- b) empyema;
- c) biliary pancreatitis;
- d) choledocholithiasis;
- e) hepatitis;
- f) cholangitis;
- g) mass;
- h) abscess;
- i) hepatic-kidney insufficiency;
- j) peritonitis (local, general).

Clinical diagnostic of acute cholecystitis

Most patients with acute cholecystitis describe a history of biliary pain. Some patients may have documented gallstones.

The disease, as a rule, begins after violation of diet: intake of much of fatty foods.

Pain syndrome. Frequently, the pain begins in the epigastric region and then localizes to the right upper quadrant.

Although the pain may initially be described as colicky, it becomes constant in virtually all cases. The pain may radiate to the right shoulder or scapula.

Dyspepsia syndrome. Frequent symptoms which disturb a patient, are nausea, vomiting, at first by gastric content, and later - with a part of bile. Afterwards feelings of swelling of stomach, delay of emptying and gases often join to them.

Examination. During examination almost in all patients subicterus of sclera even at the normal passage of bile can be observed. Patients complain for dryness in mouth. In difficult cases the tongue is usually dry, assessed by white stratification with a yellow spot in the center.

The temperature of body of most patients rises (37,2°C in patients with catarrhal cholecystitis, 38,0 - 39,0°C at its destructive forms and cholangitis).

At first hours of disease the pulse rate, usually, is relevant to the temperature, and at progress of process, especially with development of peritonitis, it becomes frequent and weak filling.

During palpation painfulness in the place of crossing of right costal arc with the external edge of direct muscle of abdomen can be observed (the *Kehr's point*). By superficial and deep palpation of right hypochondrium, as a rule, painfulness, increased gallbladder is exposed.

Murphy's sing is a delay of breathing during palpation of gallbladder on inhalation because of increasing of pain.

Kehr's sing is strengthening of pain at pressure on the area of gallbladder.

Ortner's sing - painfulness at the easy pattering on right costal arc by the edge of palm.

Mussy's sing - increasing of pain after palpation between the legs of right nodding muscle.

Blumberg's sign may be positive in patients with peritonitis.

In elderly patients, pain and fever may be absent, and localized tenderness may be the only presenting sign.

Patients with acalculous cholecystitis may present similarly to patients with calculous cholecystitis, but acalculous cholecystitis frequently occurs suddenly in severely ill patients without a prior history of biliary colic.

Special examinations

Lab. studies

Patients with uncomplicated cholelithiasis or simple biliary colic typically have normal laboratory test results.

Acute cholecystitis is associated with polymorphonuclear leukocytosis.

Choledocholithiasis with acute common bile duct obstruction initially produces an acute increase in the level of liver transaminases (alanine and aspartate aminotransferases), followed within hours by a rising serum bilirubin level. If obstruction persists, a progressive decline in the level of transaminases with rising alkaline phosphatase and bilirubin levels may be noted over several days. Concurrent obstruction of the pancreatic duct by a stone in the ampulla of Vater may be accompanied by increases in circulating lipase and amylase levels.

In patients with suspected gallstone complications, blood tests should include a complete blood count with differential, liver function panel, and amylase and lipase.

Repeated testing over hours to days may be useful in evaluating patients with gallstone complications. Improvement of the levels of bilirubin and liver enzymes may indicate spontaneous passage of an obstructing stone. Conversely, rising levels of bilirubin and transaminases with progression of leukocytosis in the face of antibiotic therapy may indicate ascending cholangitis.

Investigations in acute cholecystitis

Ultrasonography. Ultrasonographic findings that are suggestive of acute cholecystitis include the following: pericholecystic fluid, gallbladder wall thickening greater than 4 mm and sonographic Murphy sign. The presence of gallstones also helps to confirm the diagnosis (fig. 7,8).

The sensitivity and specificity of *CT/MRT* scans for predicting acute cholecystitis have been reported to be greater than 95%. Spiral CT scans and MRI have the advantage of being noninvasive, but they have no therapeutic potential and are most appropriate in cases where stones are unlikely.

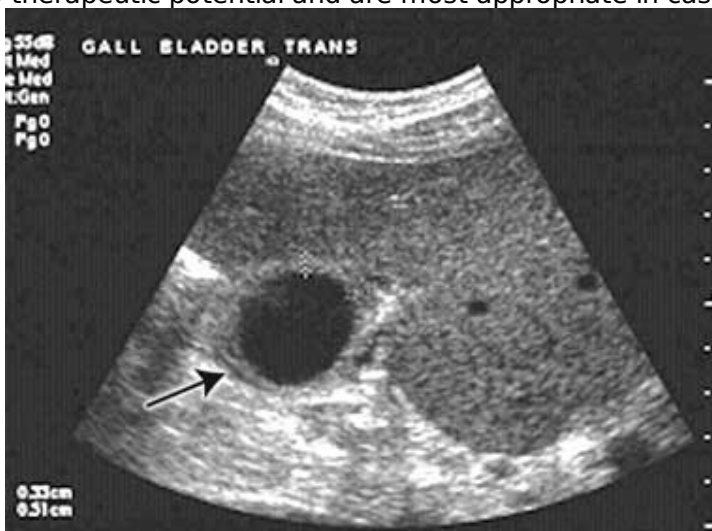

Figure 7. Ultrasound examination showed a thickened gallbladder wall and pericholecystic fluid

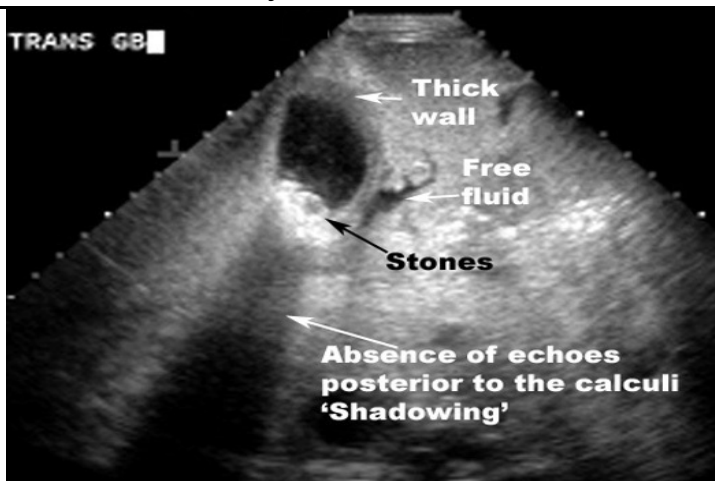

Figure 8 Ultrasound findings: thick gallbladder wall, stones in gallbladder, absence of echoes posterior to the calculi -“Shadowing”

Findings suggestive of cholecystitis include wall thickening (>4 mm), pericholecystic fluid, subserosal edema, intramural gas, and sloughed mucosa (fig. 9).

Endoscopic retrograde cholangiopancreatography may be useful in patients at high risk for common duct gallstones if signs of common bile duct obstruction are present (fig. 10).

Endoscopic retrograde cholangiopancreatography allows visualization of the anatomy and may be therapeutic by removing stones from the common bile duct. Disadvantages include the need for a skilled operator, high cost, and complications such as pancreatitis, which occurs in 3-5% of cases.

Differential diagnosis of acute cholecystitis

Perforated peptic ulcer. For this disease the *Mondor's triad* (“knife-like” pain, tension of muscles of front abdominal wall and ulcerous anamnesis) and positive *Spizharny's sign* are characteristic (disappearance of hepatic dullness). On the abdominal X-ray gram under the right copula of diaphragm free gaze can be found.

Right-side kidney colic. Pain at right-side kidney colic also can be localized in right hypochondrium. However, it is always accompanied by disorders of urination. Kidney pain often irradiates downward along passing of ureter. For this pathology micro- or macrohematuria, presence of renal concrements exposed at sonography and on the urograms. Absence of renal function during chromocystoscopy can be characteristic.

Acute appendicitis. It is needed always to remember, that the subhepatic location of the pathologically changed appendix is also able to show up pain in right hypochondrium. However, for patients with acute appendicitis beginning of pain in epigastric area, absence of hepatic anamnesis, expressed dyspeptic phenomena, inflammatory changes from the side of gallbladder at sonography are inherent.

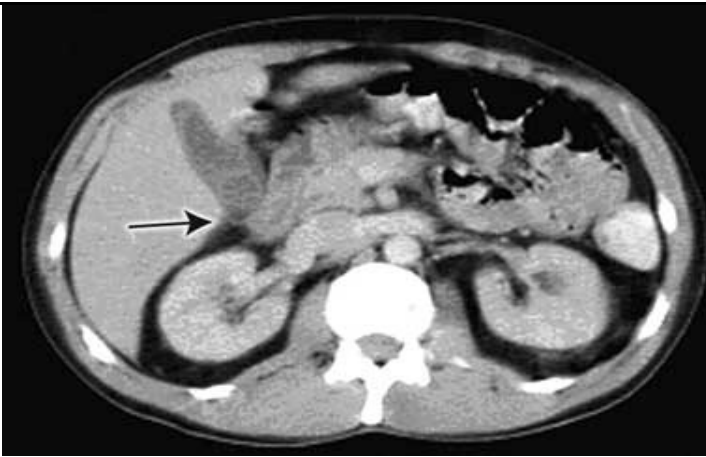


Figure 9. Computed tomography on admission showed pericholecystic inflammation, suggesting acute cholecystitis, and a possible gallstone.

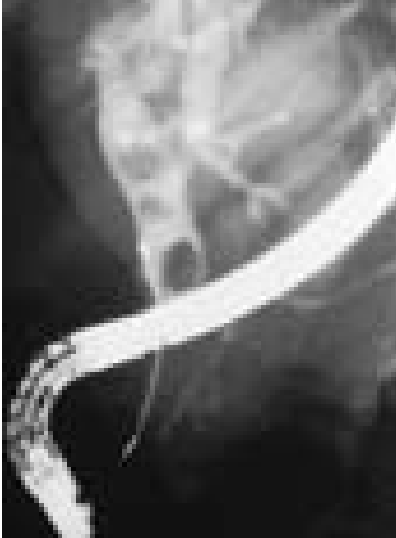

Figure 10 Endoscopic retrograde cholangiopancreatography

Heart attack, myocardial infarction. The so called cholecysto-cardial syndrome which often imitates stenocardia pain, suspicion of heart attack or myocardial infarction can develop. Electrocardiography examination is decisive in establishment of diagnosis. However, laparoscopy is applied in doubtful cases.

Acute pancreatitis. Acute pancreatitis is accompanied by the expressed upper abdominal pain. During palpation in left costal-vertebral corner patients feel painfulness (*Mayo-Robson's sign*).

Treatment of acute cholecystitis

For acute cholecystitis, initial treatment is conservative:

- local abdominal hypothermia;
- bowel rest;
- intravenous hydration;
- analgesia with NSAID;
- spasmolytical therapy;
- intravenous antibiotics.

Although not initially an infective process, broad-spectrum antibiotics are used and should be guided by local microbiological policy to target the most common organisms found in the biliary tract. These include *Escherichia coli*, *klebsiella*, *enterobacter* and *enterococcus* species. Anaerobes are less significant but include *clostridium* and *bacteroides* species.

Following successful conservative treatment most patients are discharged from hospital for future

elective laparoscopic cholecystectomy. If acute cholecystitis resolves, laparoscopic cholecystectomy may be done 4 - 6 weeks later. Delayed surgery carries the risk of recurrent biliary complications.

For frail and elderly patients who have only a single attack, or mild recurrent episodes, conservative management may be the mainstay of treatment.

Indications for urgent operation are:

- peritonitis;
- inefficacy of conservative treatment during 24 - 48 hours (retention of abdominal pain and muscles resistance, increasing of body's temperature and polymorphonuclear leukocytosis, revealing of Blumberg's sign, jaundice).

In cases of severe inflammation, shock, or if the patient has higher risk for general anesthesia (required for cholecystectomy), the managing physician may elect to have an interventional radiologist insert a percutaneous drainage catheter into the gallbladder ("percutaneous cholecystostomy tube") and treat the patient with antibiotics until the acute inflammation resolves. The patient may later warrant cholecystectomy if their condition improves.

Gallbladder removal, cholecystectomy, can be accomplished via open surgery or a laparoscopic procedure. Laparoscopic procedures can have less morbidity and a shorter recovery stay. Open procedures are usually done if complications have developed or the patient has had prior surgery to the area, making laparoscopic surgery technically difficult. A laparoscopic procedure may also be "converted" to an open procedure during the operation if the surgeon feels that further attempts at laparoscopic removal might harm the patient. Open procedure may also be done if the surgeon does not know how to perform a laparoscopic cholecystectomy. Preparation of patients undergoing cholecystectomy is similar for both urgent open and laparoscopic procedures.

Surgical incisions for open cholecystectomy are: line oblique incision in right subcostal region (is rarely performed because of the tendency for herniation); upper middle line laparotomy. Laparoscopic cholecystectomy is performed using 4 considerably smaller incisions (fig. 11).

The phases of operation are: visual inspection of abdominal cavity and operative confirmation of diagnosis; puncture of gallbladder if it is distending; dissection and visualization of Kalo's trigonum structures; cutting of cystic duct and artery with ligation or clipping (fig. 12); removing of gallbladder (fig. 13); control of bleeding and bile leak; sanitation and drainage of abdominal cavity.

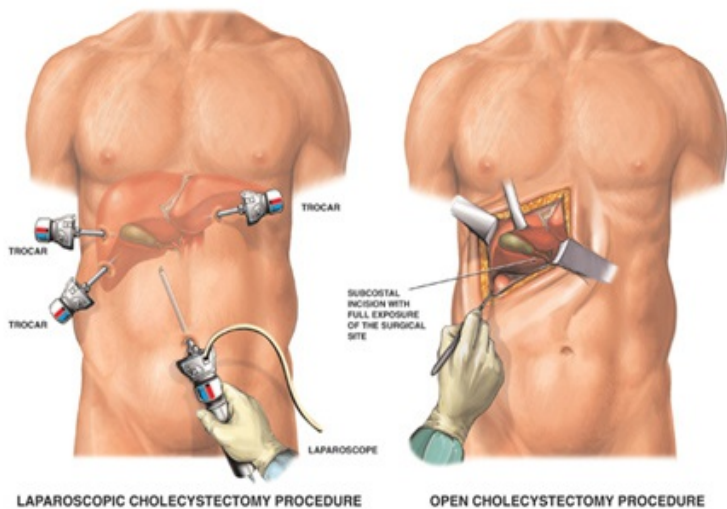


Figure 11. Open and laparoscopic procedures

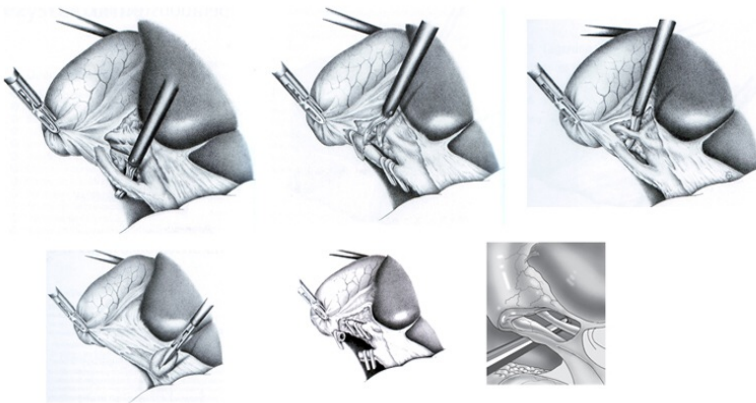


Figure 12. Dissection of Kalo's trigonum structures

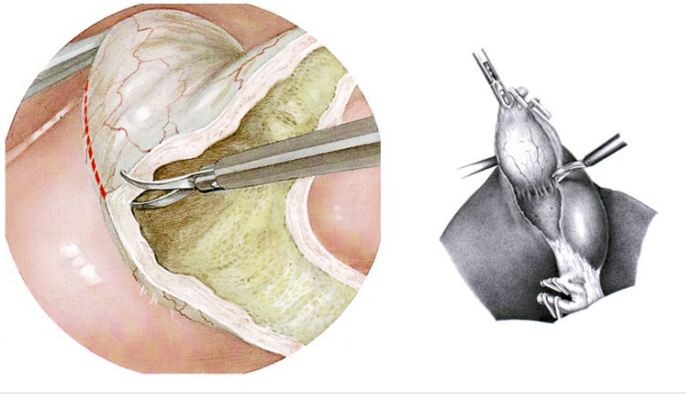


Figure 13. Removing of gallbladder

Complications of cholecystectomy:

- bile leak ("biloma");
- bile duct injury (about 5-7 out of 1000 operations. Open and laparoscopic surgeries have essentially equal rate of injuries, but the recent trend is towards fewer injuries with laparoscopy. It may be that the open cases often result because the gallbladder is too difficult or risky to remove with laparoscopy);
- abscess;
- wound infection;
- bleeding (liver surface and cystic artery are most common sites);
- hernia;
- organ injury (intestine and liver are at highest risk, especially if the gallbladder has become adherent/scarred to other organs due to inflammation (e.g. transverse colon);
- deep vein thrombosis, pulmonary embolism (risk can be decreased through use of sequential compression devices on legs during surgery);
- fatty acid and fat-soluble vitamin malabsorption.

Postoperative treatment

Administer intravenous antibiotics postoperatively. The length of administration is based on the operative findings and the recovery of the patient.

Antiemetics and analgesics are administered to patients experiencing nausea and wound pain..

A liquid diet may be started when bowel function returns.

Follow-up care

After hospital discharge, patients must have a light diet and limit their physical activity for a period of 4 weeks - 3 months based on the surgical approach (i.e., laparoscopic or open cholecystectomy). The patient should be evaluated by the surgeon in the clinic to determine improvement and to detect any possible complications.

Following cholecystectomy, about 5-10% of patients develop chronic diarrhea. This is usually attributed to bile salts. The frequency of enterohepatic circulation of bile salts increases after the gallbladder is removed, resulting in more bile salt reaching the colon. In the colon, bile salts stimulate mucosal secretion of salt and water.

Postcholecystectomy diarrhea usually is mild and can be managed with occasional use of over-the-counter antidiarrheal agents. More frequent diarrhea can be treated with daily administration of a bile acid binding resin.

Following cholecystectomy, a few individuals experience recurrent pain resembling biliary colic. The term "postcholecystectomy syndrome" is sometimes used for this condition.

Many patients with postcholecystectomy syndrome have long-term functional pain that was originally misdiagnosed as being of biliary origin. Diagnostic and therapeutic efforts should be directed at the true cause.

Some individuals with postcholecystectomy syndrome have an underlying motility disorder of the sphincter of Oddi, termed biliary dyskinesia, in which the sphincter fails to relax normally following ingestion of a meal. The diagnosis can be established in specialized centers by endoscopic retrograde cholangiopancreatography.

Prognosis

For uncomplicated cholecystitis, the prognosis is excellent, with a very low mortality rate. In patients who are critically ill with cholecystitis, the mortality rate approaches 50-60%, especially in the setting of peritonitis.

Chapter 3 Acute pancreatitis

The pancreas is a gland located in the upper, posterior abdomen and is responsible for insulin production and the manufacture and secretion of digestive enzymes leading to carbohydrate, fat, and protein metabolism. Approximately 80% of the gross weight of the pancreas supports exocrine function, while the remaining 20% is involved with endocrine function.

In acute pancreatitis there are not only symptoms of acute inflammation in the pancreas are present. There are the sings of hemorrhages and necrotic processes, which are caused by autodigestion of tissues by pancreatic enzymes. Secondary infection and multiorgan system failure may be associated with autodigestion process.

The overall mortality rate of patients with acute pancreatitis is 10-15%. Patients with biliary pancreatitis tend to have a higher mortality rate than patients with alcoholic pancreatitis. In patients with severe disease (necrosis and/or organ failure), the mortality rate is approximately 30%.

Anatomy of hepato-pancreato-duodenal region is demonstrated at figure 14.

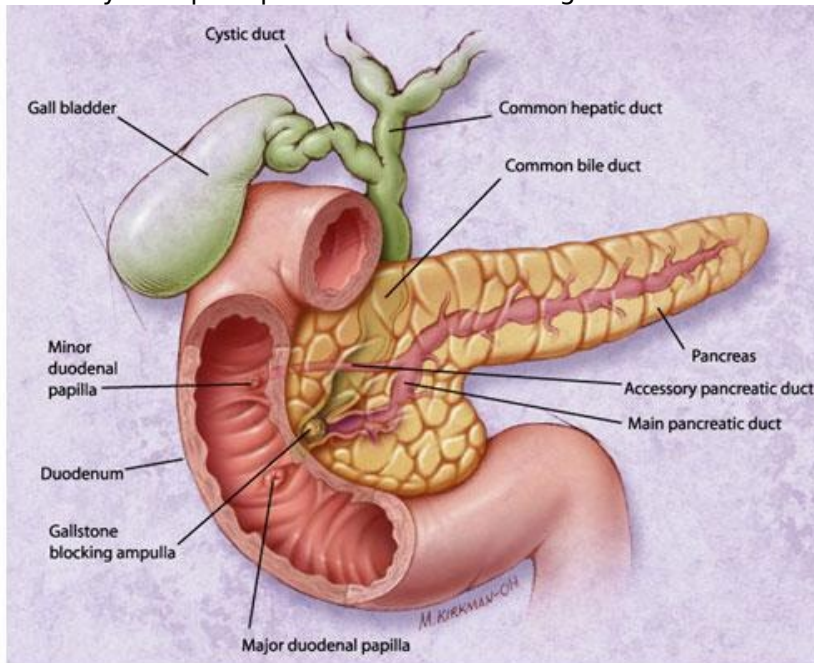


Figure 14. Anatomy of hepato-pancreato-duodenal region

Etiology

- Bile and digestive – pancreatic reflux.
- Obstruction and hypertension of biliary and pancreatic ducts.
- Blood supply disturbance of pancreas.
- Allergic and toxic process.

- Peptic ulcer disease.
- Injuries.

A number of factors are capable of initiating acute pancreatitis although their mechanism of action is not known. Alcoholism and biliary tract disease are the processes most commonly associated with pancreatitis: together they account for 80% of acute cases.

The most common cause of acute pancreatitis is *gallstones passing into the bile duct* and temporarily lodging at the sphincter of Oddi. The risk of a stone causing pancreatitis is inversely proportional to its size.

Alcohol. Most commonly, the disease develops in patients whose alcohol ingestion is habitual over 5-15 years. Alcoholics are usually admitted with an acute exacerbation of chronic pancreatitis.

Acute pancreatitis may be the first manifestation of a *tumor* causing pancreatic duct obstruction: pancreatic carcinoma should be considered in non-alcoholic patients in whom no biliary disease is identified.

Infectious agents which have been implicated as a cause of pancreatitis include mumps virus, coxsackie virus, Mycoplasma and parasites.

Many drugs are capable of causing acute pancreatitis: these include thiazide diuretics, 6-mercaptopurine, azathioprine, oestrogens, frusemide, methyldopa, sulphonamides, tetracycline, pentamidine, enalapril, and procainamide.

Patients with *types I and V hypertriglyceridaemia* frequently suffer from pancreatitis, usually associated with extremely high levels of serum triglycerides. However, hypertriglyceridaemia can also be the result rather than the cause of pancreatitis.

Postoperative pancreatitis can be fatal and is often due to iatrogenic pancreatic trauma. Pancreatitis following cardiopulmonary bypass is being recognized with increasing frequency. The majority of cases are mild or even subclinical, but evidence of severe pancreatitis is found in 25% of patients who die following cardiac surgery.

Abdominal trauma causes an elevation of amylase and lipase levels in 17% of cases and clinical pancreatitis in 5% of cases. Pancreatic injury occurs more often in penetrating injuries (e.g., from knives, bullets) than in blunt abdominal trauma (e.g., from steering wheels, horses, bicycles). Blunt injury may crush the gland across the spine, leading to a ductal injury in that location.

Toxins. Exposure to organophosphate insecticide can cause acute pancreatitis. In Trinidad, the sting of the scorpion *Tityus trinitatis* is the most common cause of acute pancreatitis.

Hypercalcemia cause can lead to acute pancreatitis. Causes include hyperparathyroidism, excessive doses of vitamin D, familial hypocalciuric hypercalcemia and total parenteral nutrition.

Developmental abnormalities of the pancreas. Two developmental abnormalities are associated with pancreatitis: anomaly of pancreatic ducts and annular pancreas.

Sphincter Oddi dysfunction can lead to acute pancreatitis by causing increased pancreatic ductal pressures.

Pathophysiology

Acute pancreatitis may occur when factors involved in maintaining cellular homeostasis are out of balance. The initiating event may be anything that injures the acinar cell and impairs the secretion of zymogen granules, such as alcohol use, gallstones and certain drugs. In addition, acute pancreatitis can develop when ductal cell injury leads to delayed or absent enzymatic secretion.

Once a cellular injury pattern has been initiated, cellular membrane trafficking becomes chaotic, with the following deleterious effects:

- 1) lysosomal and zymogen granule compartments fuse, enabling activation of trypsinogen to trypsin;
- 2) intracellular trypsin triggers the entire zymogen activation cascade;
- 3) secretory vesicles are extruded across the basolateral membrane into the interstitium, where molecular fragments act as chemoattractants for inflammatory cells.

Activated neutrophils then exacerbate the problem by releasing superoxide or proteolytic enzymes (cathepsins B, D, and G; collagenase; and elastase).

Finally, macrophages release cytokines that further mediate local (and, in severe cases, systemic) inflammatory responses. The early mediators defined to date are tumor necrosis factor- α , interleukin-6, and interleukin-8.

These mediators of inflammation cause an increase in pancreatic vascular permeability, leading to hemorrhage, edema, and eventually pancreatic necrosis. As the mediators are excreted into the circulation, systemic complications can arise, such as bacteremia due to gut flora translocation, acute respiratory distress syndrome, pleural effusions, gastrointestinal hemorrhage and renal failure.

In mild pancreatitis the inflammatory response is well controlled. There may be oedema, usually confined to the pancreas, but tissue necrosis is uncommon. In severe pancreatitis the response is uncontrolled, leading to more widespread tissue injury and the many systemic manifestations of the disease. An inflammatory exudate rich in proteolytic enzymes, kinins, and vasoactive substances escapes from the pancreas into the lesser sac, retroperitoneum and peritoneal cavity. It can then be absorbed into the systemic circulation leading to shock, respiratory failure and renal failure.

The aetiology of shock in the early phase of acute pancreatitis is multifactorial. Sequestration of fluid in the interstitium, or the third space (intestinal tract), results in intravascular fluid depletion. However, restoration of a euvolaemic status, as indicated by central venous pressure and pulmonary capillary wedge pressure measurements may not restore normal blood pressure and haemodynamic. Kinins, serotonin and vasoactive amines have been implicated as mediators of diminished peripheral vascular resistance and increased vascular permeability. Patients have high concentration of these substances in the peritoneal fluid during acute pancreatitis. Removal of this fluid by peritoneal lavage reverses the haemodynamic alterations.

A failure of systemic vascular resistance increases appropriately in the face of hypovolaemia and inability of the myocardium to compensate appropriately for this loss of peripheral resistance by increasing cardiac output. This is attributed to a myocardial depressant factor.

Circulating lipases and phospholipases destroy surfactant. Development of atelectasis and pneumonia is possible. Plevritis may occur as a result of pleura injuries by enzymes.

The mechanisms underlying the development of renal failure are: hypotension and hypovolaemia, reductions in glomerular filtration, toxic injuries of renal cells.

Classifications

Savelyev V.S. (1983)

Clinical – anatomical forms

- Edematous pancreatitis.
- Fatty pancreatitis.
- Hemorrhagic pancreatitis.
- Mixed pancreatitis.
- Purulent pancreatitis.

Periods

- Period of hemodynamic disturbances and pancreatogenic shock.
- Period of functional insufficiency of parenchymatous organs.
- Period of degenerative and purulent complications.

Complications

- Toxic: pancreatogenic pleuritis, "pancreatic lung", hepatic and kidney necrosis, erosive-hemorrhagic gastropathy, delirium, coma.
- Necrotic: pancreatic mass, pancreatic abscess, abdominal abscess, phlegmon of retroperitoneal fatty tissue, pseudocyst of pancreas.
- Visceral: external and internal fistulas.
- Erosive hemorrhage.
- Peritonitis.
- Vessels thrombosis.

Atlanta's classification, Beger H.G., 1991

- Interstitial pancreatitis.
- Pancreonecrosis (aseptical, inflectional).
- Parapancreatitis (fluid in parapancretical fatty tissue).
- Pseudocyst of pancreas.
- Abscess of pancreas.

Clinical diagnostic of acute pancreatitis

The cardinal symptom of acute pancreatitis is abdominal pain, which is characteristically dull, boring, and steady. Usually, the pain is sudden in onset and gradually intensifies in severity until reaching a constant ache. Most often, it is located in the upper abdomen, usually in the epigastric region, but it may be perceived more on the left or right side, depending on which portion of the pancreas is involved. The pain radiates directly through the abdomen to the back in approximately one half of cases. The duration of pain varies but typically lasts more than a day.

Nausea and vomiting are often present along with accompanying anorexia. Diarrhea can also occur.

Positioning can be important, because the discomfort frequently improves with the patient in the supine position.

Atypical acute pancreatitis may be misdiagnosed. In a study of patients with pancreatitis discovered at

autopsy, 13% presented with abdominal pain, 19% had disease that occurred in the postoperative setting and 68% presented with various cardiac, pulmonary, hepatic, renal, abdominal and metabolic disturbances.

The following physical examination findings vary with the severity of the disease.

Fever and tachycardia are common abnormal vital signs.

Abdominal tenderness, muscular guarding and distension are observed in most patients. Bowel sounds are often hypoactive due to gastric and transverse colonic ileus. Guarding tends to be more pronounced in the upper abdomen.

A minority of patients exhibit jaundice

Some patients experience dyspnea, which may be caused by irritation of the diaphragm (resulting from inflammation), pleural effusion, or a more serious condition, such as acute respiratory distress syndrome.

In severe cases, hemodynamic instability is evident and hematemesis or melena sometimes develops (erosive-hemorrhagic gastropathy). In addition, patients with severe acute pancreatitis are often pale, diaphoretic and listless.

Cullen's sign - bluish discoloration around the umbilicus.

Grey-Turner's sign - reddish-brown discoloration along the flanks resulting from retroperitoneal blood dissecting along tissue planes.

Mondor's sign - violet spots on the body and face.

Holsted's sign - cyanosis of skin of abdominal wall.

Grunvald's sign - petechial skin rash in the navel area.

Korte's sign - regional tension of anterior abdominal wall in epigastria region, along the projection of pancreas.

Mayo - Robson's sign - palpation pain in the left costal-vertebral angle.

Goby's sign - abdominal distension in upper region.

Voskresensky's sign - absence of pulsation of abdominal aorta in epigastria region (sign of parapancreatic infiltration).

Patients may have a ruddy erythema in the flanks secondary to extravasated pancreatic exudate.

Erythematous skin nodules may result from focal subcutaneous fat necrosis. These are usually not more than 1 cm in size and are typically located on extensor skin surfaces. In addition, polyarthrititis is occasionally seen.

Special examinations

The main tasks of special investigations are:

- Differential diagnosis with other abdominal and extraabdominal diseases.
- Detect the form (pancreatitis or pancreonecrosis).
- Detect the previous system disorders for immediate correction.

Lab. studies

Amylase and lipase. Serum amylase and lipase levels are typically elevated in persons with acute pancreatitis. Amylase or lipase levels at least 3 times above the reference range are generally considered diagnostic of acute pancreatitis.

The level of serum amylase or lipase does not indicate whether the disease is mild, moderate, or severe, and monitoring levels serially during the course of hospitalization does not offer insight into prognosis.

Liver-associated enzymes. Determine alkaline phosphatase, total bilirubin, aspartate aminotransferase and alanine aminotransferase levels to search for evidence of gallstone pancreatitis.

Calcium, cholesterol and triglycerides. Determine these levels to search for an etiology of pancreatitis (hypercalcemia or hyperlipidemia) or complications of pancreatitis (hypocalcemia resulting from saponification of fats in the retroperitoneum). However, be wary of the fact that baseline serum triglyceride levels can be falsely lowered during an episode of acute pancreatitis.

Serum electrolytes, BUN, creatinine, and glucose. Measure these to look for electrolyte imbalances,

renal insufficiency, and pancreatic endocrine dysfunction.

CBC count. Hemoconcentration at admission (an admission hematocrit value greater than 47%) has been proposed as a sensitive measure of more severe disease. Leukocytosis may represent inflammation or infection.

C-reactive protein. A C-reactive protein (CRP) value can be obtained 24-48 hours after presentation to provide some indication of prognosis. Higher levels have been shown to correlate with a propensity toward organ failure. A CRP value in double figures (i.e., >10 mg/dL) strongly indicates severe pancreatitis. CRP is an acute-phase reactant that is not specific for pancreatitis.

Arterial blood gases. Measure ABGs if a patient is dyspneic. Whether tachypnea is due to acute respiratory distress syndrome or diaphragmatic irritation must be determined.

Trypsin and its precursor trypsinogen-2 in both the urine and the peritoneal fluid have been evaluated as possible markers for acute pancreatitis but are not widely used..

Imaging studies

Abdominal radiography. This modality has a limited role in acute pancreatitis. These radiographs are primarily used to detect free air in the abdomen, indicating a perforated viscus, as would be the case in a perforated ulcer. In some cases, the inflammatory process may damage peripancreatic structures, resulting in a colon cut-off sign, a sentinel loop, or an ileus. The presence of calcifications within the pancreas may indicate chronic pancreatitis.

Chest radiography can help to detect lung and pleural complications.

Abdominal ultrasonography. This is the most useful initial test in determining the etiology of pancreatitis and is the technique of choice for detecting gallstones. In the setting of acute pancreatitis, sensitivity is reduced to 70-80%. In addition, the ability to identify choledocholithiasis is limited. Ultrasonography cannot measure the severity of disease.

Some complications (pancreatic mass, pancreatic abscess, abdominal or retroperitoneal abscess, pseudocyst of pancreas, peritonitis) can be diagnosed.

Abdominal CT scanning. This is generally not indicated for patients with mild pancreatitis unless a pancreatic tumor is suspected (usually in elderly patients). CT scanning is always indicated in patients with severe acute pancreatitis and is the imaging study of choice for assessing complications. Scans are seldom needed within the first 72 hours, because inflammatory changes are often not radiographically present until this time.

Contrast-enhanced CT of the pancreas is diagnostic and can show (*fig. 15,16*):

- enlargement of pancreas due to edema;
- peripancreatic inflammation: linear strands in the peripancreatic fat;
- phlegmon;
- hemorrhagic: enlarged pancreas with increased density due to hemorrhage;
- necrosis: on contrast enhanced phases the necrotic pancreatic parenchyma will show decreased or no enhancement when compared with normally enhancing viable tissue;
- fluid in the paracolic gutter;
- fluid collections: a simple peripancreatic fluid collection will not have a well-defined capsule;
- pseudocysts: as liquifaction of necrotic pancreatic tissue progresses it will gradually take on the appearance of localized fluid collection pseudocyst;
- abscesses: diffusely enlarged pancreas with air pockets.

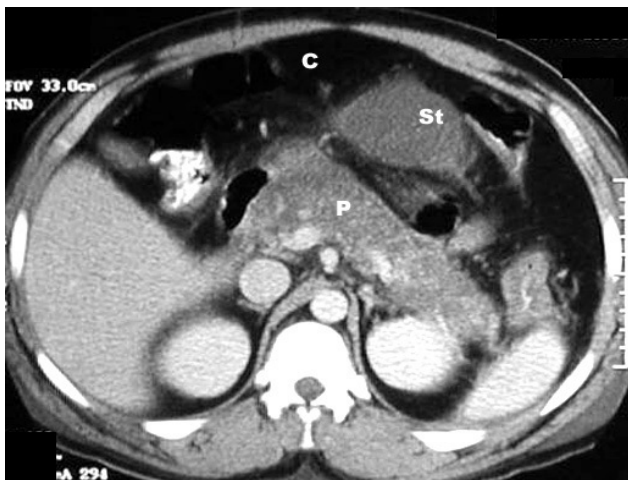


Figure 15. CT scan in acute pancreatitis

Post Contrast CT findings reveal diffusely enlarged pancreas with low density from edema. C: colon, St: stomach,

P: pancreas

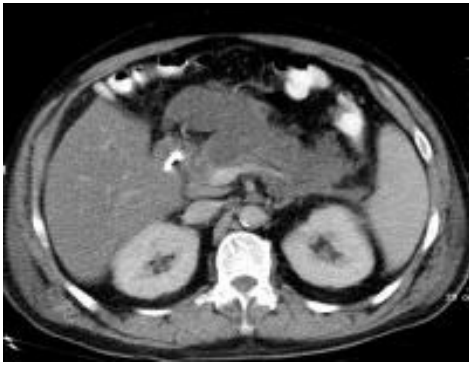


Figure 16. Acute pancreatitis, pancreatic necrosis.

Note the nonenhancing pancreatic body anterior to the splenic vein. Also present is peripancreatic fluid extending anteriorly from the pancreatic head.

Abdominal CT scans also provide prognostic information based on the following grading scale developed by Balthazar:

- A - normal.
- B - enlargement.
- C - peripancreatic inflammation.
- D - single fluid collection.
- E - multiple fluid collections.

The chances of infection and death are virtually nil in grades A and B but steadily increase in grades C through E. Patients with grade E pancreatitis have a 50% chance of developing an infection and a 15% chance of dying.

Dynamic spiral CT scanning is used to determine the presence and extent of pancreatic necrosis. Focal or diffuse areas of unenhanced parenchyma on the second study suggest pancreatic necrosis.

Magnetic resonance cholangiopancreatography (MRCP) has an emerging role in the diagnosis of suspected biliary and pancreatic duct obstruction.

Endoscopic ultrasonography (EUS) is an endoscopic procedure that allows a high-frequency ultrasound transducer to be inserted into the gastrointestinal tract. EUS is often helpful in evaluating the cause of severe pancreatitis, particularly microlithiasis and biliary sludge, and can help identify periampullary lesions better than other imaging modalities.

Procedures

Endoscopic retrograde cholangiopancreatography is dangerous in patients with acute pancreatitis and should never be used as a first-line diagnostic tool in this disease.

The indications for this procedure are:

- 1) if a patient has severe acute pancreatitis that is believed, and is seen on other radiographic studies, to be secondary to choledocholithiasis;
- 2) if a patient has biliary pancreatitis and is experiencing worsening jaundice and clinical deterioration despite maximal supportive therapy.

CT-guided needle aspiration. This procedure is used to differentiate infected necrosis and sterile necrosis in patients with severe necrotizing pancreatitis.

Treatment of acute pancreatitis

For acute pancreatitis, initial treatment is conservative.

Analgesics, spasmolytics. Narcotic analgetics are dangerous in patients with acute pancreatitis because of sphincter Oddi constriction.

Relief of vomiting. Drainage of the stomach with a probe, metaclopramid (eeruleal, reglan) 10-20 mg; osetron (ondansetron, navoban, tropisetron).

Fluid replacement. The most important requirement in the early treatment of pancreatitis is maintenance of adequate hydration. If the patient becomes hypovolaemic, and the splanchnic circulation is compromised, the pancreas may become ischaemic, with the potential for the development of complicated pancreatitis.

With considerable reduction of arterial blood pressure - dopamine 5-7 mkg/kg of the body weight; for relief of angiospasm - benzohexamethonium 0.15 mg / kg of the body weight or pentamine 0.25 - 0.3 mg/kg of the body weight every 6 hours; for reduction of vascular permeability - hydrocortisone 1,000-1,500 mg/day.

Treatment of hypoxaemia. Fluid replacement, normalization of peripheral microcirculation is adequate in majority of patients. In the most severely ill patients intubation and ventilatory support is indicated.

Minimizing of pancreatic secretion

Bowel rest, nasogastric tube.

Local hypothermia.

H₂-receptor or H-pomp blockers. They are useful for inhibition of pancreatic enzymes secretion and prevention of acute upper digestive tract ulcerations.

Atropine.

5-fluorouracil (500 mg /d).

Nutritional support. Patients with severe acute pancreatitis often cannot be fed for several days. Once severe pancreatitis has developed total parenteral nutrition should be instituted. Intravenous fat emulsions do not exacerbate pancreatitis in patients with normal triglyceride levels. If triglyceride levels are raised, however, fat emulsion should not be used. Total parenteral nutrition should be continued until the patient appears clinically well.

Antibiotic therapy. Antibiotics are generally ineffective in preventing the late septic complications of acute pancreatitis, and their use may even promote selection of organisms that are more difficult to treat later on. The best variants are:

- third and fourth - generations of cephalosporin's;
- quinolones and metronidazole;
- carbapenems.

Antiprotease therapy. Gordox, Contrical. They are useful and effective only as inhibitors of kinins.

Treatment of metabolic disturbances includes correction of hypocalcaemia, hypoalbuminaemia, hypomagnesaemia, hypokalaemia, control of blood glucose.

Surgical care

In patients with acute pancreatitis common indications for surgery are:

- Progressive peritonitis.
- Progressive multiorgan system failure.
- Gallstones pancreatitis without effect of conservative treatment during 24-48h.
- Erosive hemorrhage.
- Bowel perforations.
- Septic complications.

Operations

- Peritoneal lavage.
- Gallstones pancreatitis: cholecystectomy and, if still necessary, common bile duct tube.
- Abdominization.
- Necrectomy.
- Surgical management in necrotizing process into the retroperitoneum, perirenal spaces, and mesentery.
- Drainage by percutaneous aspiration of peripancreatic fluid collections.
- Percutaneous drainage of pancreatic abscesses (under CT or US control).

Chapter 4 Perforated peptic ulcer

The frequency of peptic ulcer disease is estimated 6% to 15% in the general population. Most individuals do not have clinically significant ulcer.

Approximately 10% of young men have H pylori, and the proportion of people with the infection increases steadily with age. The incidence of duodenal ulcer has been decreasing over the past 3-4 decades.

Lifetime prevalence of perforation in patients with peptic ulcer disease is approximately 5%. With nonsteroidal anti-inflammatory drugs (NSAID)-related ulcers, the incidence of perforation is 0.3%. Emergency operations for peptic ulcer perforation carry a mortality risk of 6-30%. Most deaths result from postoperative complications.

Etiology

1. Contributes factor: progressive destruction of stomach or duodenal wall.

Ulcers of the stomach and duodenum are caused chiefly by the effects of hydrochloric acid, produced by the parietal cells of the stomach, and by lack of protection of the mucosa against this acid. Acid production is the most important factor as far as duodenal ulcer is concerned, but cannot be the only factor, since the severity of duodenal ulcers and their responses to therapy do not vary directly with the amount of gastric acid secreted.

Additional factors are important in the production of gastric ulcers. Gastric contents can be retained for a much longer period than duodenal contents and are not neutralized rapidly. The mucous membrane of the stomach must normally be protected continuously from the damaging effect of the hydrochloric acid which it secretes. This protective layer consists of an adherent layer of mucus which is separated from the gastric mucosa by a bicarbonate layer that normally neutralizes any hydrochloric acid diffusing back through the mucous layer. The mucous layer also protects the gastric mucosa against other noxious agents such as bile, alcohol, and aspirin and other irritating drugs.

Secretion of acid by the parietal cells of the stomach is influenced by several mechanisms. Stimulation by the vagus nerves accounts for about 50% of acid secretion. Gastrin that is secreted by the antral mucosa causes 40 to 45% of the secretion and the remaining 5 to 10% is due to gastrin that comes from the intestinal tract from various APUD cells.

Production of gastric mucus should presumably vary according to the blood supply of the organ. Experimental studies have shown that prostaglandins increase the mucosal blood supply and increase the bicarbonate level and thickness of the mucous layer; they may, therefore, play an important role in the protection of the gastric mucosa.

Causes of gastric ulcers vary in importance depending upon the location of these ulcers. In 1965 Johnson observed the different behavior of ulcers in different portions of the stomach and classified them into three groups. In patients with type 1 ulcers, located in the body of the stomach, gastric acid secretion as determined by secretory tests is low. Here inadequate mucosal protection and back-diffusion of hydrochloric acid through the protective bicarbonate and mucous layer into the gastric mucosa seem to be involved in the disease. Silent suggested it is in this location that alternating waves of gastric acid from above and refluxing alkaline secretions from the duodenum destroy the protective layer of mucus.

Johnson's type 2 gastric ulcers (those combined with a present or past duodenal ulcer) and type 3 (those in the prepyloric area) behave more like duodenal ulcers; here the effects of acid production appear to be more important.

A peptic ulcer occurs when an alteration occurs in the aggressive and/or protective factors such that the balance is in favor of gastric acid and pepsin. Any process that increases gastric acidity (e.g., individuals with increased maximal and basal acid output), decreases prostaglandin production (e.g., NSAIDs), or interferes with the mucous layer (e.g., *Helicobacter pylori* infection) can cause such an imbalance and lead to peptic ulcer disease.

H. pylori infection that follows an antral predominant pattern leads to an inflammatory state in which high levels of tumor necrosis factor-alpha (TNF-alpha) and other cytokines are produced. These stimulate gastric acid production directly by increasing gastrin release from G cells and inhibit somatostatin production by antral D cells. This leads to a net increase in gastric acid secretion, which leads to an increased acid load in the duodenum, overwhelming the mucosal defense.

H. pylori can then colonize the duodenal mucosa and adhere to cells. This adherence leads to a variety of second-messenger signals, which invoke an immunologic response against those cells causing mucosal damage by host neutrophils and other inflammatory cells.

H. pylori also affect the gastric and duodenal mucous layer because this organism produces proteases that degrade the protective mucous layer.

Moreover, *H. pylori* infection decreases the production of epidermal growth factor, which normally promotes healing of gastric and duodenal mucosa.

H. pylori organisms produce urease. Urease hydrolyzes urea to ammonia and carbon dioxide. Hydroxide ions produced by equilibration of ammonia with water may damage the gastric and duodenal mucosa.

2. *Causes factor: increasing of pressure in stomach lumen* (more food intake, physical training).

Classifications

Forms of perforation (Savelyev V.S., 1976)

- Perforation of duodenal or gastric ulcer into the free abdominal cavity.
- Covered perforation.
- Atypical perforation (into the lesser sac, retroperitoneal fatty tissue).

Clinical stages (Neimark N.I., 1972)

- stage of shock;
- stage of illusion;
- stage of peritonitis.

Clinical manifestations

Clinically the perforations are distinguished into three phases: shock, stage of illusion and peritonitis (Mondor, 1939).

Stage of shock (lasts for about 6 hours)

- Intensive upper abdominal pain at the time of perforation (*Delafua* compares it with “pain due to stabbing with a dagger”).
- *Elicer’s sing* – irradiation of pain to the right shoulder or scapula.
- Tenderness of abdominal wall. In elderly patients tension of muscles of abdominal wall is absent or insignificant through old-age relaxation of muscles.
- Percussion of liver will reveal attenuated dullness due to free gas.
- Auscultation will reveal a silent abdomen.
- Blumberg’s sing.
- Temperature is normal.
- Blood pressure may be lost.
- Pulse is rapid.

Stage of illusion (lasts for about 6 – 12 hours)

- As more exudate accumulates, chemical irritation of peritoneum becomes less, the patient feels better with less pain.
- The same sings may be found by rigidity becomes less.
- Abdominal distention will start.
- Temperature becomes elevated.

Stage of peritonitis

- The patient is extremely toxic with tachycardia and high temperature.
- The abdomen is rigid, distended and silent.
- Blumberg’s sing.
- Blood pressure is often lost.

Covered perforation (A.M. Shnicler, 1912). In this pathology the perforation is closed by fibrin, by omentum or sometimes – by food particle. After that some amount of stomach content and air left into the abdominal cavity. This protective mechanism leads to relief from stomachache, but moderate tenderness of abdominal wall in right epigastria region persists (*Ratner’s sing*). On percussion hepatic dullness is doubtful. During X-Ray examination it is not always possible to mark gas in right hypochondrium

Consequences of the covered perforation are: repeated perforation with development of classic clinical signs; subdiaphragmatic or subhepatic abscess; complete closing of defect by surrounding tissue with gradual convalescence of patient.

The atypical perforation is the perforation, at which gastric or intestinal content does not enter the abdominal cavity, but enters the retroperitoneal space (ulcers of posterior wall of duodenum), large or small omentum (ulcers of lesser curvature of stomach), hepatoduodenal ligament.

In such patients during the perforation pain is not acutely expressed. During palpation insignificant rigidity of muscles of anterior abdominal wall is observed. On occasion, especially in the late stages of disease, can be hypodermic emphysema and crepitation.

The differential diagnosis includes acute cholecystitis, acute pancreatitis, strangulating intestinal obstruction, acute appendicitis, perforation of some other portion of the intestinal tract, and mesenteric thrombosis. A past history of ulcer disease is predictive, but in 30% of patients perforation is the first manifestation of peptic ulcer disease.

Diagnosis programmer

X-Ray examination of abdominal cavity organs for presence of free gas (pneumoperitoneum, fig. 17).

Fibergastroduodenoscopy + X-Ray examination.

Ultrasound of abdominal cavity (pneumoperitoneum, fig. 18) + laparocentesis (peritoneal exudate).

Laparoscopy.

Laparotomy.

CT with oral contrast may also demonstrate extravasation of contrast in the presence of a perforated ulcer. If history and physical examination raise the possibility of perforation, upright chest radiography and an upper digestive tract contrast study with water-soluble contrast are the diagnostic studies of choice. Do not perform CT scanning in this situation.

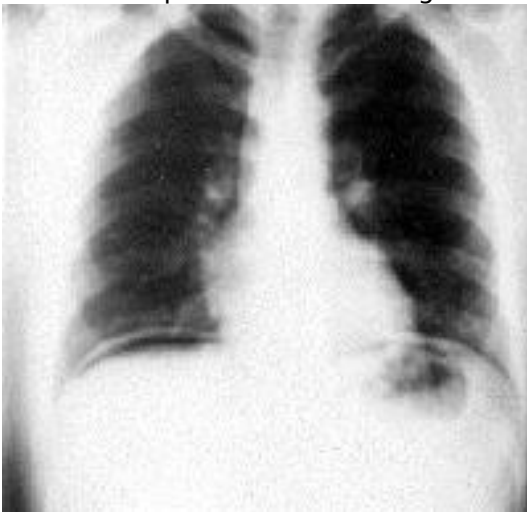

Figure 17. X-Ray examination of abdominal cavity, pneumoperitoneum

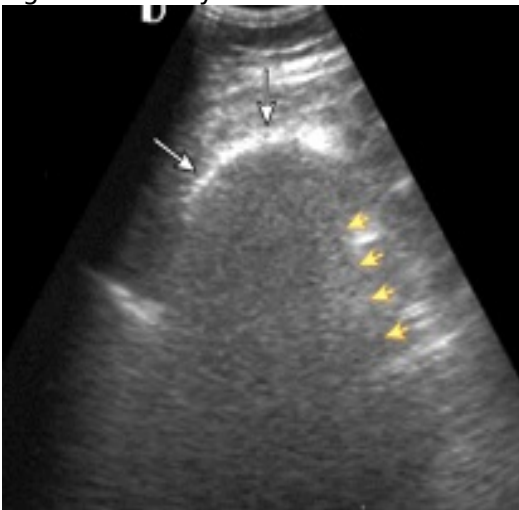


Figure 18. Ultrasound of abdominal cavity, pneumoperitoneum

Lab. Studies

CBC count (Leucocytosis with left shift is found in most cases.)

Serum gastrin level. Gastrin levels greater than 1000 pg/mL are suggestive of gastrinoma.

Serum H pylori antibody detection. Antibodies (immunoglobulin G [IgG]) to H pylori can be measured in serum, plasma, or whole blood. However, results from whole blood tests using finger sticks are less reliable.

Urea breath tests. Urea breath tests are used to detect active H pylori infection by testing for the enzymatic activity of bacterial urease. In the presence of urease produced by H pylori, labeled carbon dioxide (heavy isotope, carbon-13, or radioactive isotope carbon-14) is produced in the stomach, absorbed into the bloodstream, diffused into the lungs, and exhaled.

Fecal antigen tests. Fecal antigen testing is used to identify active H pylori infection by revealing the presence of H pylori antigens in stools.

This test is more accurate than antibody testing and less expensive than urea breath tests.

Treatment of perforated peptic ulcer

Tactic of treatment in patients with perforated peptic ulcer is surgical.

Conservative treatment is temporary measure when surgery is impossible. Conservative treatment includes the following (Taylor's method):

- nasogastric decompression;- replacement of fluid and electrolytes;
- proton pump inhibitor;
- broad-spectrum antibiotics;
- hypothermia of abdominal wall.

Conservative treatment is associated with high risk of septic complications (formation of abscess, peritonitis).

Surgical treatment

Preoperative details. Fluid resuscitation should be initiated as soon as the diagnosis is made. Essential steps include insertion of a nasogastric tube to decompress the stomach and a Foley catheter to monitor urine output. Intravenous infusion of fluids is begun, and broad-spectrum antibiotics are administered. In select cases, insertion of a central venous line may be necessary for accurate fluid resuscitation and monitoring. As soon as the patient has been adequately resuscitated, emergent surgery should be performed.

Simple closure of perforation. Simple closure of perforation may be performed by laparotomy or laparoscopy.

The 1st step of the operation is the exploration of the abdominal cavity, which allows confirming the diagnosis of generalized peritonitis. In addition, it allows differentiating between the septic and the clinical peritonitis, and especially it permits to determine the possibility of the laparoscopic repair.

A very important step of the operation is the aspiration of peritoneal fluid, which should be as complete as possible. This is followed by extensive irrigation of the abdominal cavity.

The next step is the exact localization of the perforation, which sometimes may be covered by the liver, gallbladder or omentum. In this case, the perforation is identified on the anterior aspect of the duodenum.

Ideal repair of the perforation is direct closure by absorbable or non-absorbable sutures. Treatment of perforation may include also an epiploplasty in addition to the closure. An omental flap is chosen and is placed over the suture and fixed with 1 or 2 absorbable stitches. When a reliable direct suture of the opening cannot be achieved, closure can be completed by application of biological glue. The operation is completed by final extensive abdominal irrigation.

Ulcer excision, pyloroduodenoplasty

Ulcer excision and pyloroduodenoplasty is the simplest open surgical treatment for duodenal ulcer and in selected instances it can be used in the treatment of bleeding, obstruction, perforation. The operation carries low morbidity and mortality rates.

The operation usually consists of a Judd procedure. A longitudinal excision is made around the ulcer

defect beginning from distal stomach to the proximal duodenum and closed transversely, so that the action of the pyloric valve is obliterated. In other cases, when the proximal duodenum is badly deformed by scar, a Finney procedure (essentially a side-to-side gastroduodenostomy) or a Jaboulay procedure (gastric resection plus side-to-side gastroduodenostomy) is used after ulcer excision.

Various types of vagotomy

Three types of vagotomy require consideration. Bilateral truncal vagotomy denervates the entire stomach and the gastrointestinal tract to the left colon. When combined with other operations it is extremely effective in reducing the number of recurrent ulcers. However it does carry some deleterious side-effects, reducing the ability of the stomach to empty and being followed by other late motility disturbances, occasional vagus diarrhea, and reflux alkaline gastritis. Selective vagotomy denervates the entire stomach but leaves nerves to the gallbladder, pylorus, and bowel intact. From a practical point of view this operation is more difficult and time-consuming than truncal vagotomy, appears to have nearly equivalent results, and has attracted few supporters. Proximal gastric vagotomy can be used without pyloroplasty.

Partial gastrectomy

The usual procedure involves resection of the distal two-thirds of the stomach followed by either a Billroth I or a Billroth II anastomosis. In our opinion the operation is neater and more accurate when sutures are inserted by hand, although stapling instruments can be used. Partial gastrectomies are usually performed for type 1 gastric ulcer and for combination of duodenal ulcer perforation with decompensate stenosis.

Postoperative treatment

Administer intravenous antibiotics postoperatively. The length of administration is based on the operative findings and the recovery of the patient.

Antiemetics and analgesics are administered to patients experiencing nausea and wound pain..

A liquid diet may be started when bowel function returns.

To prevent gastric and duodenal ulcer recurrence and their complications proton pump inhibitor or H₂ - receptors antagonist is administered.

Follow-up care

After hospital discharge, patients must have a light diet and limit their physical activity for a period of 4 weeks - 3 months based on the surgical approach (i.e., laparoscopic or open procedure). The patient should be evaluated by the surgeon in the clinic to determine improvement and to detect any possible complications.

Continuous supportive therapy (for a month or even years) with half the dose of proton pump inhibitors or H₂ - receptors antagonists is administered.

Prognosis

For uncomplicated surgery, the prognosis is excellent, with a very low mortality rate.

Chapter 5 Peptic ulcer acute hemorrhage

Peptic ulcer acute hemorrhage is a common occurrence throughout the world. In France, a recent report concludes that the mortality from peptic ulcer acute hemorrhage has decreased from about 11% to 7%; however, a similar report from Greece finds no decrease in mortality.

Patients typically present with an ulcer that has bled or is actively bleeding. Approximately 80% of ulcers stop bleeding. The overall mortality rate is approximately 10%. Rebleeding or continued bleeding is associated with increased mortality. Comorbidities increase the probability of rebleeding in patients after endoscopic therapy. An increasing amount of evidence in the literature states that therapy with high-dose proton pump inhibitors may decrease the rate of rebleeding after endoscopic therapy. By increasing the gastric pH above 6, the clot is stabilized.

This patient population has become progressively older, with significant comorbidities that increase mortality.

Pathophysiology

Duodenal ulcer disease is strongly associated with *Helicobacter pylori* infection. The organism causes disruption of the mucous barrier and has a direct inflammatory effect on gastric and duodenal mucosa. Eradication of *H pylori* has been demonstrated to reduce the risk of recurrent ulcers and, thus, recurrent ulcer hemorrhage.

NSAIDs are the second major etiology of ulcer hemorrhage because of their effect on cyclooxygenase-1, which leads to impaired mucosal defense to acid. The use of cyclooxygenase-2 inhibitors has been shown to reduce the risk of ulcer hemorrhage, although only when not combined with aspirin therapy. Recent concerns have been raised about an increase in myocardial infarction and stroke in patients taking selective cyclooxygenase-2 inhibitors.

The combination of *H pylori* infection and NSAID use may increase the risk of ulcer hemorrhage.

As the ulcer burrows deeper into the gastroduodenal mucosa, the process causes weakening and necrosis of the arterial wall, leading to the development of a pseudoaneurysm. The weakened wall ruptures, producing hemorrhage. The flow through the vessel varies with the radius: small increases in vessel size can mean much larger amounts of blood flow and bleeding. Visible vessels usually range from 0.3-1.8 mm.

Massive hemorrhage has been reported from larger vessels. The larger vessels are located deeper in the gastric and duodenal submucosa and serosa. Larger branches of the left gastric artery are found high on the lesser curvature, while the pancreaticoduodenal artery and its major branches are located posteroinferiorly in the duodenal bulb.

The size of the vessel is important in the prognosis in that larger vessels cause faster blood loss, with more severe hypotension and more complications, especially in older patients.

The main disturbances in patients with acute peptic ulcer bleeding are:

1. Acute loss of blood leads to rapid reduction of cardiac output.
2. Activation of simpatico-adrenal system results in peripheral vasoconstriction and centralization of blood supply.
3. Mechanisms of compensation are supplemented with hemodilution (displacement of interstitial liquid into vessels) and increasing of aldosterone production).
4. After loss less 20% of volume of blood circulation the bleeding stops and in absence of hemorrhagic compensation the disturbances of circulation of blood are not observed.
5. After loss more 20% of volume of blood circulation without the proper compensation of hemorrhage such patients can survive, however always there are considerable disturbances of blood circulation with disturbance of functions of liver and kidneys.
6. Inadequate peripheral blood supply leads to hypoxia, stimulates anaerobic glycolysis and results in free radical metabolites (metabolic acidosis).
7. . Reological disturbances result in embolism and thrombosis in microcirculation bloodstream.
8. Arteriovenous shunts open, multiple organ failure develops ("sock" lungs, kidneys, liver).
9. Loss of blood cells results in immunodeficiency.

Classifications

Stages of loss of blood (Shalimov A.A., 1987)

1. 20% of volume of blood circulation.
2. 20% - 30% of blood circulation.
3. More than 30% of blood circulation.

Forrest endoscope classification (Forrest J.A.H., 1974)

- *Forrest I.* Active bleeding.
- *Forrest II.* Temporary hemostasis. Ulcer is covered with hematin, thrombus, blood clot (risk of bleeding recurrence 40%).
- *Forrest III.* There aren't signs of bleeding (risk of bleeding recurrence 4%).

History

It is needed to remember, that for diagnosis anamnesis is very important. The patient history findings include weakness, dizziness, syncope associated with hematemesis (coffee ground vomitus), melena (black stools with a rotten odor) and hematochezia (red or maroon stool).

More patients tell about their peptic ulcer disease. Sometimes bleeding has occurred repeatedly or patients has undergone surgery for perforated ulcer in the past. In some patients a gastric or duodenum ulcer was not diagnosed before and correctly collected anamnesis revealed that the patient had stomach-ache. Patients often tell that pain in upper part of abdomen which occurred a few days prior to bleeding, suddenly disappears the onset of bleeding (*the Bergmann's sign*).

Patients may have a history of previous dyspepsia (especially nocturnal symptoms), ulcer disease, early satiety, and NSAID or aspirin use. Many patients with peptic ulcer acute hemorrhage who are taking nonsteroidal anti-inflammatory drugs present without dyspepsia but with hematemesis or melena as their first symptom. Low-dose aspirin (81 mg) has been associated with peptic ulcer acute hemorrhage with or without the addition of NSAID therapy. Patients with a prior history of ulcers are at an especially increased risk for peptic ulcer acute hemorrhage when placed on aspirin or NSAID therapy and should receive continuous acid suppression with a proton pump inhibitor. Because recurrence of ulcer disease is common, history findings are relevant.

Patients may present in a more subacute phase with a history of dyspepsia and occult intestinal bleeding manifesting as a positive fecal occult blood test result or as iron deficiency anemia.

A history of recent aspirin ingestion suggests that the patient may have nonsteroidal anti-inflammatory drug gastropathy with an enhanced bleeding diathesis from poor platelet adhesiveness.

A history of chronic alcohol use of more than 50 g/d or chronic hepatitis (B or C) increases the risk of hemorrhage, gastric antral vascular ectasia, or portal gastropathy.

The presence of postural hypotension indicates more rapid and severe blood loss.

Clinical manifestation

In patients with peptic ulcer disease bleeding starts mainly at night. Vomiting can be the first sign, mostly, with gastric localization of ulcers. Vomiting, as a rule, is "coffee-ground" in appearance.

Sometimes it is with fresh blood or blood clots.

The black stool is the permanent symptom of ulcer bleeding, with an unpleasant smell ("melena") that can take place few times in day.

Bloody vomiting and "melena" is accompanied by worsening of the general condition of patient. An acute weakness, dizziness, noise in a head and darkening in eyes, sometimes - loss of consciousness. A collapse with the signs of hemorrhagic shock can also develop.

In patients with ulcer bleeding there are typical changes of hemodynamic indexes: the pulse is rapid, weak filling and tension, arterial pressure is mostly reduced. These indexes need to be observed in the dynamics, as they can change during the short interval of time.

There is pallor of skin and visible mucosas at an examination. The stomach sometimes is moderately enlarged, but more frequently it is pulled in, soft on palpation. In upper part it is possible to notice hyperpigmented spots - as a result of prolonged application of hot-water bottle. Pain on deep palpation in the area of right hypochondrium (duodenal ulcer) or in a epigastric area (gastric ulcer) is often observed in penetrated ulcers. *Mendel's sign* - pain on percussion in the projection of piloroduodenal area - may be indicated.

In the examination of patients with the gastrointestinal bleeding digital examination of rectum is obligatory. It needs to be performed at the first examination, because information about the presence of black excreta ("melena") is important. In addition, it is sometimes possible to expose the tumour of rectum or haemorrhoidal nodes which are also the source of bleeding.

Clinical variants

It is necessary always to remember that complication of peptic ulcer by bleeding happens considerably more frequently, than it is diagnosed. The clinical signs and staging of disease depends on the degree of loss of blood. Usually, 50-55 % of moderate bleeding (microbleeding) are unseen. In fact profuse bleeding with the loss 50-60 % of the volume of circulatory blood could stop the heart and cause the death of patient.

For loss of 20% of volume of blood circulation (I stage) typically: rapid pulse rate to 90-100 per min., decreasing of arterial blood pressure to 90/60 mm Hg. The excitability of patient changes by lethargy, however consciousness is clear, breathing is frequent. After the bleeding stops and in absence of hemorrhagic compensation the disturbances of circulation of blood are not observed.

In patients with the II stage of hemorrhage (loss of 20% - 30% of blood circulation) the general condition needs to be estimated as average. Expressed pallor of skin, sticky sweat, lethargy. Pulse rate - 120-130 per min., weak filling and tension, arterial blood pressure - 90-80/50 mm Hg. In the first few hours the spasm of vessels (centralization of blood circulation) arises after bleeding. Without the proper compensation of hemorrhage such patients can survive, however always there are considerable disturbances of blood circulation with disturbance of functions of liver and kidneys.

The III stage of hemorrhage (more than 30% of blood circulation). The pulse rate in such patients is 130-140 per min., and arterial blood pressure - from 60 to 0 mm Hg. Consciousness is almost always darkened, acutely expressed adynamy. Central vein pressure is low. Oliguria is observed, that can change to anuria. Without active and directed correction of hemorrhage the patient can die.

Amount of bleeding doesn't always correspond to the general condition of patient. It can depend on compensatory mechanism of the organism, rate of loss of blood and the presence of accompanying pathology.

It is needed to remember, that the ulcer bleeding can accompany the perforation of ulcer. During perforation, ulcers are often accompanied by bleeding. Correct diagnosis of these two complications has important value in tactical approach and in the choice of method of surgical treatment. In fact simple suturing of perforated and bleeding ulcer can lead to complications in the postoperative period, as profuse bleeding and cause the necessity of repeat operation.

Differential diagnosis

With wide use of gastroduodenoscopy the question of differential diagnosis of bleeding is less significant. However such a problem arises due to impossibility to use this method of examination when the general condition of patient is bad or taking into account other reasons. Differential diagnosis is conducted in

bleeding of nonulcer origin, which can arise in different parts of digestive tract.

For bleeding from the *varicose veins of esophagus* in patients with portal hypertension with liver cirrhosis. This type of bleeding is massive and leading to considerable hemorrhage. Vomiting of fresh blood, expressed tachycardia, falling of arterial pressure are observed. In such patients it is possible to find the signs of cirrhosis of liver and portal hypertension.

The cancer of stomach in the destruction stage can be also complicated by bleeding. Such bleeding often are not massive, and chronic character is carried mostly with gradual growth of anaemia. Worsening of the general condition of patient, loss of weight, decreasing of appetite and waiver of meat are inherent in this pathology.

The gastric bleeding can be related to the diseases of the cardio vascular system (atherosclerosis, hypertensive disease), This is mainly seen in the older people.

Other diseases to be differentiated from ulcer bleeding are: the Mallory-Weiss syndrome, benign tumours of stomach and duodenum (more frequent leiomyoma), hemorrhagic gastritis, acute (stress) erosive defects of stomach, arteriovenous fistula of mucosa.

Diagnosis program

1. Anamnesis and physical examination.
2. Digital examination of rectum.
3. EFGDS.
4. 4. Lab studies.
5. 5. Other necessary instrumental examinations.

Lab studies

CBC with platelet count and differential: CBC is necessary to assess the level of blood loss. Where possible, having the patient's previous results is useful to gauge the level of blood loss. CBC should be checked frequently (4-6h) during the first day.

Basic metabolic profile (BMP): The BMP is useful to evaluate for renal comorbidity; however, blood in the upper intestine can elevate the BUN level as well.

Measurement of coagulation parameters is necessary to assess for continued bleeding. Abnormalities should be corrected rapidly.

Prothrombin time/activated partial thromboplastin time.

Liver profile: The liver profile can identify hepatic comorbidity and suggest underlying liver disease.

Calcium level: A calcium level is useful to identify the patient with hyperparathyroidism as well as to monitor calcium in patients receiving multiple transfusions of citrated blood.

Gastrin level: A gastrin level can identify the rare patient with gastrinoma as the cause of peptic ulcer bleeding and multiple ulcers.

Imaging studies

Chest and abdominal radiographs should be ordered to exclude aspiration pneumonia, effusion, and esophageal perforation; abdominal scout and upright films should be ordered to exclude perforated organs and ileus.

Barium contrast studies are not usually helpful and can make endoscopic procedures more difficult (i.e., white barium obscuring the view) and dangerous (i.e., risk of aspiration).

CT scan and ultrasonography may be indicated to evaluate liver disease with cirrhosis, cholecystitis with hemorrhage, pancreatitis with pseudocyst and hemorrhage, aortoenteric fistula, and other unusual causes of upper gastrointestinal hemorrhage.

Nuclear medicine scans may be useful to determine the area of active hemorrhage.

Angiography may be useful if bleeding persists and endoscopy fails to identify a bleeding site. As salvage therapy, embolization of the bleeding vessel can be as successful as emergent surgery in patients who have failed a second attempt of endoscopic therapy.

Procedures

Nasogastric lavage. This procedure may confirm recent bleeding (coffee ground appearance), possible active bleeding (red blood in the aspirate that does not clear), or a lack of blood in the stomach (active bleeding less likely but does not exclude an upper gastrointestinal lesion).

A nasogastric tube is an important diagnostic tool, and tube placement can reduce the patient's need to vomit. Placement for diagnostic purposes is not contraindicated in patients with possible esophageal varices.

The characteristics of the nasogastric lavage fluid (e.g., red, coffee grounds, clear) and the stool (e.g., red, black, brown) can indicate the severity of the hemorrhage. Red blood with red stool is associated with an increased mortality rate from more active bleeding compared with negative aspirate findings with brown stool.

Tactic and choice of treatment method

Main tasks in treatment of patients with acute peptic ulcer hemorrhage are:

1. Stopping of flow of blood.
2. Removal of consequences of bleeding (correction of blood volume circulation, cardiac, renal, liver

disturbances and others).

3. Antysecretory therapy.
4. Moving off blood from intestine lumen (clysis).
5. Immunocorrection.

Stopping of bleeding may be achieved using 3 ways: endoscope, conservative therapy, operation.

Most patients (85-90%) respond to endoscopic therapy. After fiber-optic endoscopy inspection and visualization of the source of bleeding endoscopy hemostasis has been performed using one from next ways:

- periulcerous injection of vasoconstrictors and procoagulators;
- electro coagulation;
- laser coagulation;
- plasma coagulation;
- covering over the bleeding ulcer with polymer film;
- clipping of vessels.

A combination of therapies has become more common. Injection therapy is applied first to better clarify the bleeding site, especially in the actively bleeding patient; then, heater probe or bipolar probe coagulation is applied. Injection therapy can also be performed prior to endoscopic placement of hemoclips. Injection therapy is useful prior to laser therapy to reduce the heat sink effect of rapidly flowing blood prior to laser coagulation.

The use of argon plasma coagulation for ulcer hemorrhage, however, there are significant theoretical and experimental considerations from animal models about the use of a noncontact monopolar cautery in this situation..

The bipolar probe consists of alternating bands of electrodes producing an electrical field that heats the mucosa and the vessel.

The electrodes are coated with gold to reduce adhesiveness. The probes are stiff to allow adequate pressure to the vessel to appose the walls and thus produce coagulation when the energy is transmitted (heat energy by the heater probe, electrical-field energy by the bipolar probe). Careful technique is required to heat-seal the perforated vessel.

Alternatively, epinephrine (1:10,000, 1:20,000) can be injected in 0.5-mL aliquots around the base of the vessel. This causes coagulation by compression, with perhaps some additive effect of activation of platelet factor 3 or vasoconstriction. Other solutions that have been used for injection are ethanol (more necrosis), hypertonic saline, sterile water, and cyanoacrylate.

Epinephrine injection is often used to reduce the volume of bleeding so that the lesion can be better localized and then treated with a coaptive technique (i.e., heater probe, gold probe). Such combination therapy has become more frequent and has evolved into the standard technique.

Laser therapy is rarely used. To perform laser coagulation, the area near the vessel is first injected with epinephrine to reduce blood flow (reducing the heat-sink effect); then, the laser is applied around the vessel (producing a wall of edema). Caution must be observed to avoid drilling into the vessel with the laser, causing increased bleeding.

Hemostatic clips have recently become available in the United States. With careful placement of the clip, closing the defect in the vessel is possible. Usually, multiple clips are applied. The clipping devices are single-use devices with a single clip deployed with each instrument.

Argon plasma coagulation is a technique in which a stream of electrons flows along a stream of argon gas. The coagulation is similar to monopolar cautery with the current flow going from a point of high current density, the point of contact of the gas with the mucosa, to an area of low current density, the conductive pad on the patient's body. The current flows through the body in an erratic path to the pad. This monopolar cautery technique is similar to the laser technique in that energy is delivered to the vessel for coagulation with apposition of the vessel walls. This technique was not effective for visible vessels larger than 1 mm.

Contraindications to emergency fiber-optic endoscopy include:

- severe cardiac and lung decompensation;
- acute myocardial infarction;
- impaired cardiopulmonary status and bleeding diathesis;

Emergency esophagogastroduodenoscopy may be more difficult or impossible if the patient has had previous oropharyngeal surgery or radiation therapy to the oropharynx.

The presence of a Zenker diverticulum can make intubation of the esophagus more difficult.

After endoscopy hemostasis conservative therapy has been started.

It must include:

- prescription of haemostatics (intravenously the aminocapronic acid 5 % ~ 200-400 ml, chorus calcium 10 % - 10,0 ml, vicasol 1 % -3,0 ml);

- increasing of the volume of circulatory blood (gelatin, reopoliglukine, salt blood substitutes);
- preparations of blood (fibrinogen - 2-3g, cryoprecipitate);
- blood substitutes therapy (red corpuscles mass, washed red corpuscles, plasma of blood);
- H2-receptor antagonists or proton pump inhibitors;
- antacids and adsorbents (almagel, phosphalugel, maalox - for 1-2 dessert-spoons through 1 hour after food intake).

It is important to wash stomach with ice water and the use 5 % solution of aminocaproic acid 1 tablespoon every 20-30 minutes.

Absolute indications for surgical treatment are:

1.) prolonged bleeding;
2.) recurrent bleeding;
3.) perforated bleeding ulcer.

Relative indications for surgery may be established in patients with high risk of recurrent bleeding: Forrest I or II attached to "gigantic" (more than 20 mm in diameter) ulcers, combination of bleeding with stenosis and penetration.

It's better to perform surgery in the patient at high risk of recurrent bleeding during 24-48 hours after removal of consequences of acute bleeding.

Angiographic embolization is an option in the patient at high risk for surgical intervention. Angiographic embolization of the gastroduodenal or the left gastric arteries may be effective, but there are dangers involved. A foreign body may slip from the gastroduodenal into the hepatic artery and lead to hepatic necrosis; one in the left gastric artery may lead to necrosis of the upper portion of the stomach.

Operations for massively bleeding duodenal ulcers

The site of bleeding must be determined. If the source is the gastroduodenal artery, it must be ligated as the first step. This procedure involves suture of the artery, either above the duodenum as it emerges from the hepatic artery or within the duodenal lumen, suture of the caudal portion of the artery within the duodenum or of the two major branches; the superior pancreaticoduodenal and the right gastroepiploic; and of the transverse pancreatic artery. Heavy, non-absorbable sutures are used. In other instances the duodenum may be boggy and bleeding from multiple areas; in such instances it may be impossible to identify single vessels to ligate.

As soon as bleeding has been controlled, a definitive operation can be carried out. We believe that ulcer excision and pyloroduodenoplasty with/without selective vagotomy is best. A major determinant in the selection is the experience of the surgeon. If vagotomy wasn't performed, H2-receptor antagonists or proton pump inhibitors has been prescribed for prevention of ulcer recurrence and it's complications.

Partial gastrectomy (the usual procedure involves resection of the distal two-thirds of the stomach) is more difficult, but gives slightly better control of bleeding because it removes areas of gastritis and duodenitis that are potential sources of postoperative bleeding.

Operations for bleeding gastric ulcers

Gastric resection is preferred for bleeding gastric ulcers. A truncal vagotomy may be added if the ulcer is in the prepyloric area or if the patient has a history of a duodenal ulcer. Either a Billroth I or II anastomosis can be made.

In some patients who have high operative risks, a local excision of the ulcer may be performed. However, the chances of recurrence within a year approach nearly 50 per cent.

The most difficult stomach ulcer to treat is one located in the proximal portion. In older patients who are poor risks, a distal resection, ligation of the left gastric artery, and intragastric plication of the ulcer is recommended.

Total gastrectomy cannot be determined in a patient who continues to bleed.

Chapter 6 Bowel obstruction

Bowel obstruction is most common in surgery practice. It often leads to different complications and death of patients. Fisicion has to diagnose a case, to define the tactics of treatment, to choose the

A small-bowel obstruction (SBO)

It is caused by a variety of pathologic processes. The most common cause of SBO is postsurgical adhesions. Postoperative adhesions can be the cause of acute obstruction within 4 weeks of surgery or of chronic obstruction decades later. The incidence of SBO parallels the increasing number of laparotomies performed in developing countries. Other etiologies of SBO include malignant tumor (20%), hernia (10%), inflammatory bowel disease (5%), volvulus (3%).

SBOs can be partial or complete, simple (i.e., nonstrangulated) or strangulated. If not diagnosed and properly treated, vascular compromise leads to bowel ischemia and further morbidity and mortality. Because as many as 40% of patients have strangulated obstructions, differentiating the characteristics and etiologies of obstruction is critical to proper patient treatment.

Frequency

SBO accounts for 20% of all acute surgical admissions. Mortality and morbidity are dependent on the early recognition and correct diagnosis of obstruction. If untreated, strangulated obstructions cause death in 100% of patients. If surgery is performed within 36 hours, the mortality decreases to 8%. The mortality rate is 25% if the surgery is postponed beyond 36 hours in these patients.

Pathophysiology

Obstruction of the small bowel leads to proximal dilatation of the intestine due to accumulation of GI secretions and swallowed air. This bowel dilatation stimulates cell secretory activity resulting in more fluid accumulation. This leads to increased peristalsis both above and below the obstruction with frequent loose stools and flatus early in its course.

Vomiting occurs if the level of obstruction is proximal. Increasing small-bowel distention leads to increased intraluminal pressures. This can cause compression of mucosal lymphatics leading to wall lymphedema. With even higher intraluminal hydrostatic pressures, increased hydrostatic pressure in the capillary beds results in massive third spacing of fluid, electrolytes, and proteins into the intestinal lumen. The fluid loss and dehydration that ensue may be severe and contribute to increased morbidity and mortality. Strangulated SBOs are most commonly associated with adhesions and occur when a loop of

distended bowel twists on its mesenteric pedicle. The arterial occlusion leads to bowel ischemia and necrosis. If left untreated, this progresses to perforation, peritonitis, and death. Bacteria in the gut proliferate proximal to the obstruction. Microvascular changes in the bowel wall allow translocation to the mesenteric lymph nodes. This is associated with an increase in incidence of bacteremia due to *Escherichia coli*, but the clinical significance is unclear.

History

Abdominal pain (characteristic with most patients). Pain, often described as crampy and intermittent, is more prevalent in simple obstruction. Often, the presentation may provide clues to the approximate location and nature of the obstruction. Usually pain that occurs for a shorter duration of time and is colicky and accompanied by bilious vomiting may be more proximal. Pain lasting as many as several days, which are progressive in nature and with abdominal distention, may be typical of a more distal obstruction. Changes in the character of the pain may indicate the development of a more serious complication (i.e., constant pain of strangulated or ischemic bowel).

Nausea.

Vomiting. This is associated more with proximal obstructions.

Diarrhea (an early finding).

Constipation (a late finding) as evidenced by the absence of flatus or bowel movements.

Previous abdominal or pelvic surgery and/or previous radiation therapy (may be part of patient's medical history).

History of malignancy (particularly ovarian and colonic).

Physical

Abdominal distention. Duodenal or proximal small bowel has less distention when obstructed than the distal bowel has when obstructed.

Hyperactive bowel sounds occur early as GI contents attempt to overcome the obstruction.

Hypoactive bowel sounds occur late.

Exclude incarcerated hernias of groin, femoral triangle, and obturator foramina. Proper genitourinary and pelvic examinations are essential.

Look for the following during rectal examination. Gross or occult blood, which suggests late strangulation or malignancy.

Check for symptoms commonly believed to be more diagnostic of intestinal ischemia, including the following:

- fever;
- tachycardia (>100 beats/min);
- peritoneal signs.

No reliable way exists to differentiate simple from early strangulated obstruction on physical examination. Serial abdominal examinations are important and may detect changes early.

Lab Studies

Serum chemistries: Results are usually normal or mildly elevated.

Creatinine. Elevations may indicate dehydration.

CBC: WBC may be elevated with a left shift in simple or strangulated obstructions. Increased hematocrit speaks to volume state (i.e., dehydration).

Lactate dehydrogenase tests

Urinalysis

Liver panels

Imaging studies

Radiography

Order plain radiographs first for patients in whom SBO is suspected. At least 2 views, supine or flat and upright, are required. Too findings were more predictive of a higher grade or complete SBO: presence of air-fluid differential height in the same small-bowel loop and presence of a mean level width greater than 25 mm. When these findings are present, the obstruction is most likely high grade or complete. When both are absent, a low (partial)-grade SBO is likely or nonexistent. Absent or minimal colonic gas indicates SBO (*fig.19*).

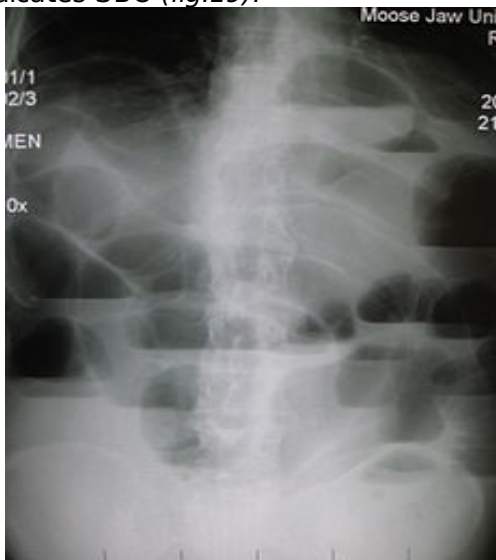


Figure 19. Multiple air fluid levels

Small bowel loops contain transverse folds known as valvulae conniventes or plica circularis. These folds are well seen in this patient with small bowel obstruction. Usually the colon is decompressed and hardly visible (*fig.20*).

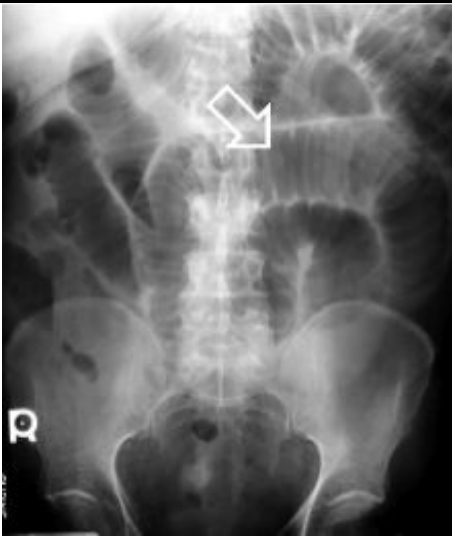


Figure 20. Plica circularis

Enteroclysis

This is valuable in detecting presence of obstruction and in differentiating partial from complete blockages. This study is useful when plain radiographic findings are normal in the presence of clinical signs of SBO or if plain radiographic findings are nonspecific. It distinguishes adhesions from metastases, tumor recurrence, and radiation damage. Enteroclysis offers a high negative predictive value and can be performed with 2 types of contrast. Barium is the classic contrast agent used in this study. It is safe and useful when diagnosing obstructions provided no evidence of bowel ischemia or perforation exists. Barium has been associated with peritonitis and should be avoided if perforation is suspected.

CT scanning

CT scanning is useful in making an early diagnosis of strangulated obstruction and in delineating the myriad other causes of acute abdominal pain, particularly when clinical and radiographic findings are inconclusive. It also has proved useful in distinguishing the etiologies of SBO, i.e., extrinsic causes such as adhesions and hernia from intrinsic causes such as neoplasms or Crohn disease. It also differentiates the above from intraluminal causes such as bezoars. CT scanning is about 90% sensitive and specific in diagnosing SBO. CT scanning is the study of choice if the patient has fever, tachycardia, localized abdominal pain, and/or leukocytosis. It is capable of revealing abscess, inflammatory process, extraluminal pathology resulting in obstruction, and mesenteric ischemia. CT scanning enables the clinician to distinguish between ileus and mechanical small bowel in postoperative patients. Obstruction is present if the small-bowel loop is greater than 2.5 cm in diameter dilated proximal to a distinct transition zone of collapsed bowel less than 1 cm in diameter (*fig.21*).

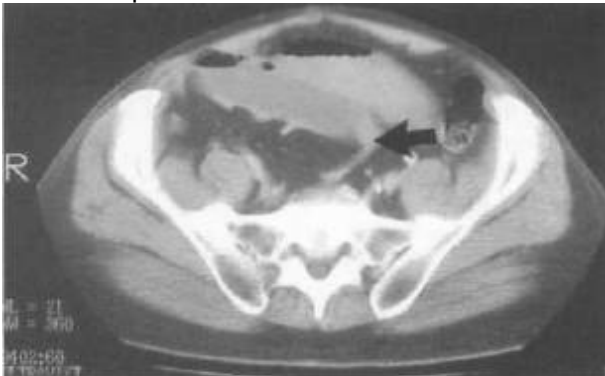

Figure 21. Note the dilated small bowel loops with a focal transition zone to distal collapsed bowel

A smooth beak indicates simple obstruction without vascular compromise; a serrated beak may indicate strangulation. Bowel wall thickening indicates early strangulation. CT scanning is useful in identifying abscesses, hernias and tumors.

Ultrasonography

Ultrasonography is less costly and less invasive than CT scanning. It may reliably exclude SBO in as many as 89% of patients. Specificity is reportedly 100%.

Ultrasonography sings of SBO:

- dilatation of small bowel lumen;
- "pendulous" movements of bowel content.

Treatment

A strangulated obstruction is a surgical emergency. In patients with a complete SBO, the risk of strangulation is high and early surgical intervention is warranted. Patients with simple complete obstructions in whom nonoperative trials fail also need surgical treatment but experience no apparent disadvantage to delayed surgery.

Adhesions. Decreasing intraoperative trauma to the peritoneal surfaces can prevent adhesion formation.

Malignant tumor. Obstruction by tumor is usually caused by metastasis. Initial treatment should be nonoperative; surgical resection is recommended when feasible.

Inflammatory bowel disease. To reduce the inflammatory process, treatment generally is nonoperative in combination with high-dose steroids. Consider parenteral treatment for prolonged periods of bowel rest. Undertake surgical treatment, bowel resection, and/or stricturoplasty if nonoperative treatment fails.

Intraabdominal abscess. CT-guided drainage is usually sufficient to relieve obstruction.

Radiation enteritis. If obstruction follows radiation therapy acutely, nonoperative treatment accompanied by steroids is usually sufficient. If obstruction is a chronic sequel of radiation therapy, surgical treatment is indicated.

Acute postoperative obstruction. This is difficult to diagnose because symptoms often are attributed to incisional pain and postoperative ileus. Treatment should be nonoperative. If nonoperative treatment fails, surgical treatment is indicated.

Prognosis

With proper diagnosis and treatment of the obstruction, prognosis is good. Complete obstructions treated successfully nonoperatively have higher incidence of recurrence than those treated surgically.

Large bowel obstruction

Large bowel obstruction may be caused by neoplasms or anatomic abnormalities such as volvulus, incarcerated hernia, stricture or constipation.

Large bowel obstruction from an anatomic abnormality leads to colonic distention, abdominal pain, anorexia, and, late in the course, feculent vomiting. Persistent vomiting may result in dehydration and electrolyte disturbances.

Large bowel obstruction is a surgical entity. The morbidity and mortality often are related to the surgical procedure used to relieve the colonic obstruction and, in the long term, to the underlying disease

that caused the obstruction.

Colonic obstruction is most common in elderly individuals because the incidence of neoplasms and other causative diseases is higher in this population.

Hirschsprung disease resembles colonic obstruction in the pediatric population.

History

History focuses initially on the failure to pass stools or gas. One should attempt to distinguish complete bowel obstruction from partial obstruction, which is associated with passage of some gas or stools, and from ileus. Further historical questioning may be directed at the patient's current and past history in an attempt to determine the most likely cause. Complete obstruction is characterized by the failure to pass either stools or flatus and the presence of an empty rectal vault upon rectal examination, unless the obstruction is in the rectum. Partial obstruction, in which the patient appears obstipated but continues to pass some gas or stools, is a less urgent condition. Distinguishing colonic ileus from organic obstruction is important. Ileus may be suggested by abdominal pain as a dominant feature of the clinical presentation, by peritoneal signs, or by the presence of pronounced fever and leukocytosis. Large bowel obstruction, or even constipation, may be accompanied by some degree of fever or leukocytosis. Similarly, based on peritoneal signs, distinguishing the tender gas-filled and stool-filled colon observed in organic obstruction from a tender abdomen due to peritonitis is difficult. Obtaining a thorough history of previous bowel function, abdominal pain, and general systemic issues is important. History of chronic weight loss and passage of melanotic bloody stools suggest neoplastic obstruction. Conversely, a history of recurrent left lower quadrant abdominal pain over several years is more consistent with diverticulitis, a diverticular stricture, or similar problems. A history of aortic surgery suggests the possibility of an ischemic stricture.

Physical

Abdominal examination. Perform the examination in standard fashion, i.e., inspection, auscultation, percussion, and palpation. Large bowel obstruction may be characterized by diminished or, in later stages, absent bowel sounds. The abdomen is distended and may be tender. The presence of true involuntary guarding or peritoneal signs should raise the specter of another intra-abdominal process, such as an abscess. The practice of seeking rebound tenderness is misleading and potentially cruel. Many patients without peritoneal signs complain vigorously after an aggressive rebound maneuver. Seeking tenderness and pain by having the patient cough or by shaking the bed probably is more useful.

Examination of inguinal and femoral regions. This should be an integral part of the examination. Incarcerated hernias represent a frequently missed cause of bowel obstruction. In particular, colonic obstruction often is caused by a left-sided inguinal hernia with the sigmoid colon incarcerated in the hernia.

Digital rectal examination. Perform this to verify the patency of the anus in a neonate. The examination focuses on identifying rectal pathology that may be causing the obstruction and determining the contents of the rectal vault. Hard stools suggest impaction. Soft stools suggest obstipation. An empty vault suggests obstruction proximal to the level that the examining finger can reach. Fecal occult blood testing should be performed, and a positive result may suggest the possibility

of a more proximal neoplasm.

Lab Studies

Studies are directed at evaluating the dehydration and electrolyte imbalance that may occur as a consequence of large bowel obstruction and at ruling out ileus as a diagnosis. Suggestion of an abnormal anion gap also should prompt an arterial blood gas measurement and/or a serum lactate level measurement. A decreased hematocrit level, particularly with evidence of chronic iron-deficiency anemia, may suggest chronic lower gastrointestinal bleeding, particularly due to colon cancer. A stool test also should be performed, for similar reasons. Although bowel obstruction, or even constipation, may mildly elevate the WBC count, substantial leukocytosis should prompt reconsideration of the diagnosis. Ileus, secondary to an intra-abdominal or extra-abdominal infection or another process, is a possibility.

Imaging Studies

Flat and upright abdominal roentgenography demonstrates dilation of the large bowel and air fluid levels. Colonic air suggests the anatomic location of the obstruction. A dilated colon without air in the rectum is more consistent with obstruction. The presence of air in the rectum is consistent with obstipation, ileus, or partial obstruction. This finding can be misleading, particularly if the patient has undergone rectal examinations or enemas. The characteristic bird's beak of volvulus may be seen.

If differentiation between obstipation and obstruction is required, imaging with contrast is indicated (fig.22). If localization is required for surgical intervention, imaging with contrast is indicated. Water-soluble Gastrografin has important advantages over barium as a contrast agent and generally should be employed first. It usually does not cause chemical peritonitis if the patient has colonic perforation.

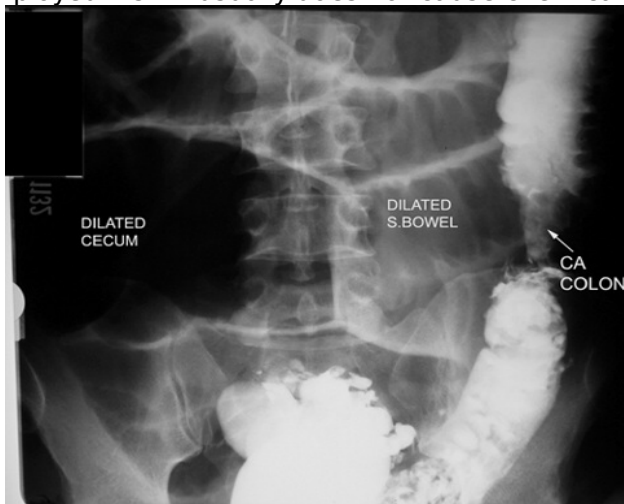

Figure 22. Left side colonic cancer with obstruction

CT scanning is not used initially in patients with large bowel obstruction unless a diagnosis has been made. CT scan, particularly with rectal contrast, may demonstrate a mass or evidence of metastatic disease.

Other tests. Fiber - optic endoscopy may be useful in evaluating left-sided colonic obstruction, including the anatomic location and pathology of the lesion. Because the cecum is not reached in such cases, the endoscopist must be alert to the possibility of incorrectly identifying anatomic landmarks and the location of the obstruction. Although flexible endoscopy is relatively comfortable for the patient and provides a better view than rigid sigmoidoscopy, the latter also may be used, depending on the availability of resources and training of personnel. Right-sided colonic obstruction is more difficult to evaluate without first administering an oral bowel preparation, which is contraindicated in the setting of bowel obstruction.

Procedures

Endoscopic reduction of volvulus. This procedure is indicated for sigmoid volvulus when peritoneal signs are absent, which would imply dead bowel or perforation. It also is indicated when evidence of mucosal ischemia is not present upon endoscopy. An experienced person should perform the procedure. A rigid sigmoidoscope may be used if a flexible instrument is not available. The endoscopist must have sufficient experience with this technique. Reduction of a volvulus does not imply cure. The sigmoid usually revolvulizes if definitive treatment is not carried out. These patients generally are admitted, subjected to mechanical bowel preparation, and managed surgically by sigmoid resection, unless contraindications are present. Barium enema for reduction of intussusception. This is useful and often successful in children in whom a pathological leading point for the intussusception is unlikely. It should be performed by an experienced radiologist because the risk of perforation is significant. In adults, typically a pathologic leading point for the intussusception is present. Success is far less likely, and patients still require surgery to deal with their pathology. Cleansing enemas. Perform these if obstipation is suspected rather than true large bowel obstruction. Also perform them to prepare the distal colon for endoscopic evaluation. Endoscopic dilation and stenting of colonic obstruction This procedure is indicated for colonic near total obstruction through which some small amount of lumen remains. The procedure may be palliative in a high-risk patient with an unresectable malignancy, accepting a risk of reobstruction of the stent, or preparatory to surgical resection. In cases in which the stent is deployed prior to surgery, it permits relief of the acute obstruction, resuscitation of the patient, and mechanical bowel preparation prior to a one-stage colonic resection and reanastomosis, thus avoiding temporary or permanent colostomy. The procedure should be performed only by an endoscopist experienced in such procedures. Surgical consultation and backup should be available, as the risk of perforation is increased during attempts at such procedures, with a potentially catastrophic result.

Medical Care

It involves resuscitation, correction of fluid and electrolyte imbalance, and nasogastric decompression to temporarily treat the obstruction and prevent vomiting and aspiration.

Surgical Care

Surgical care is directed at relieving the obstruction. In most patients, the obstructing lesion is resected. Because the colon has not been cleansed, anastomosis often is risky. After resection, most surgeons perform a proximal colostomy if the obstruction is on the left side or ileostomy if it is on the right side. In patients with substantial comorbidity and surgical risk or in the presence of an unresectable tumor, a diverting proximal colostomy or ileostomy may be performed without resection. A diverting transverse loop colostomy may be the least invasive procedure for a very ill patient with a left colonic obstruction. It permits relief of the obstruction and further resuscitation without compromising chances for a subsequent resection. A sigmoid colostomy without resection may be employed in patients with rectal obstruction that cannot be managed without a combined abdominoperineal approach. Cecostomy should not be performed because the diversion is inadequate. In younger patients some surgeons would consider primary anastomosis, rather than ileostomy, in the right colon, assuming no intraoperative hypotension, blood loss, or other complications are present. If resection and proximal colostomy or ileostomy is performed, a mucous fistula generally is extracted from the distal end, unless the obstruction is rectosigmoid, in which case the distal end may be oversewn or stapled and left to drain transanally. If the cause of the obstruction can be relieved nonsurgically, through procedures such as decompressing a volvulus, or if the obstruction is only partial, deferring surgery temporarily and supporting the patient while the large bowel is cleansed so that primary anastomosis may be performed more safely is preferable.

Further Outpatient Care

Care after discharge focuses on surgical convalescence and, if relevant, the need to care for the disease that caused the obstruction. An obstructing colon cancer may require postoperative chemotherapy, depending on the stage of the disease. The patient who is chronically obstipated may need stool softeners. If the patient has received a colostomy or ileostomy, a decision regarding whether it is temporary or permanent may have been made at the time of discharge, depending on the patient's diagnosis, comorbidity, and postoperative convalescence. Most patients who retain a rectum are, at least in principle, candidates for reanastomosis at a subsequent stage. Generally, it is performed 2-3 months after the initial operation. Careful counseling and assessment are required before proceeding with the second procedure. Counseling is directed at the risks of the second procedure because the patient must understand that this surgery is elective and that a colostomy or ileostomy is compatible with a reasonable lifestyle. Often, local colostomy support groups and meeting with other patients with colostomies are helpful at this time. Patients who had stool incontinence before their first operation, those with substantial surgical risks, and patients with decreased mental status who are cared for in nursing homes may potentially be better off without a reanastomosis. In addition, the remaining colon, both proximally and distally, must be evaluated radiographically or endoscopically to rule out synchronous colonic lesions such as neoplasms because the presence of the large bowel obstruction prevented this from being performed before the first procedure.

Prognosis

Prior to surgical decompression, the patient's overall medical condition and presence of any comorbidities that define surgical risk determine the prognosis. After surgical decompression, prognosis is determined by the underlying disease.

Ileus

After abdominal surgery, a normal physiological ileus occurs. This type of ileus spontaneously resolves within 2-3 days after sigmoid motility returns to normal. However, the terms postoperative adynamic ileus or paralytic ileus are defined as ileus of the gut persisting for more than 3 days following surgery. Ileus occurs from hypomotility of the gastrointestinal tract in the absence of a mechanical bowel obstruction. This suggests that the muscle of the bowel wall is transiently impaired and fails to transport intestinal contents. This lack of coordinated propulsive action leads to the accumulation of both gas and fluids within the bowel. Although ileus has numerous causes, the postoperative state is the most common scenario for ileus development. Frequently, ileus occurs after intraperitoneal operations, but it may also occur after retroperitoneal and extra-abdominal surgery. The longest duration of ileus is noted to occur after colonic surgery.

Causes

Causes of adynamic ileus:

Most cases of ileus occur after intra-abdominal operations.

Sepsis.

Drugs (e.g., opioids, antacids, coumarin, amitriptyline, chlorpromazine).

Metabolic (e.g., low potassium, magnesium, or sodium levels; anemia, hyposmolality).

Myocardial infarction.

Pneumonia.

Trauma (e.g., fractured ribs, fractured spine).

Biliary and renal colic.

Head injury and neurosurgical procedures.

Intra-abdominal inflammation and peritonitis.

Retroperitoneal hematomas.

Pathophysiology

According to some hypotheses, postoperative ileus is mediated via activation of inhibitory spinal reflex arcs. Anatomically, 3 distinct reflexes are involved: ultrashort reflexes confined to the bowel wall, short reflexes involving prevertebral ganglia and long reflexes involving the spinal cord. The long reflexes are the most significant. Spinal anesthesia, abdominal sympathectomy, and nerve-cutting techniques have been demonstrated to either prevent or attenuate the development of ileus. The surgical stress response leads to systemic generation of endocrine and inflammatory mediators that also promote the development of ileus. Rat models have shown that laparotomy, eventration, and bowel compression lead to increased numbers of macrophages, monocytes, dendritic cells, T cells, natural killer cells, and mast cells, as demonstrated by immunohistochemistry. Calcitonin gene-related peptide, nitric oxide, vasoactive intestinal peptide, and substance P function as inhibitory neurotransmitters in the bowel nervous system. Nitric oxide and vasoactive intestinal peptide inhibitors and substance P receptor antagonists have been demonstrated to improve gastrointestinal function.

History

Patients with ileus typically present with vague, mild abdominal pain and bloating. They may report nausea, vomiting, and poor appetite. Abdominal cramping is usually not present. Patients may or may not continue to pass flatus and stool. Physical: Patients may have distended and tympanic abdomens, depending on the degree of abdominal and bowel distension. The abdomen may be tender. A distinguishing feature is absent or hypoactive bowel sounds unlike the high-pitched sound of obstruction. The silent abdomen of ileus reveals no discernible peristalsis or succussion splash.

Lab studies

Laboratory studies and blood work should focus on evaluations for infectious, electrolytic, and metabolic derangements.

Imaging studies:

On plain abdominal radiographs, ileus appears as copious gas dilatation of both small intestine and colon. With enteroclysis, the contrast medium in patients with paralytic ileus should reach the cecum within 4 hours; if it remains stationary for longer than 4 hours, mechanical obstruction is suggested.

Medical Care

Most cases of postoperative ileus resolve with watchful waiting and supportive treatment. Patients should receive intravenous hydration. For patients with vomiting and distension, use of a nasogastric tube provides symptomatic relief.

Underlying sepsis and electrolyte abnormalities, particularly hypokalemia, hyponatremia, and hypomagnesemia, may worsen ileus. These contributing conditions are easily diagnosed and corrected.

Discontinue medications that produce ileus (e.g., opiates). The use of postoperative narcotics can be diminished by supplementation with nonsteroidal anti-inflammatory drugs (NSAIDs). NSAIDs may improve ileus by improving local inflammation and by decreasing the amount of narcotics used.

The presence of ileus does not preclude enteral feeding. Postpyloric tube feeding into the small bowel can be performed.

Use of prokinetic agents has had moderate success, a serotonin agonist, has reportedly been successful in treating ileus.

Chapter 7 Acute peritonitis

Inflammation and infection of the peritoneal cavity are commonly encountered problems in the practice of clinical medicine today. In general, the term peritonitis refers to a constellation of signs and symptoms, which includes abdominal pain and tenderness on palpation, abdominal wall muscle rigidity, and systemic signs of inflammation.

Relevant anatomy

The peritoneum is the largest and most complex serous membrane in the body. It forms a closed sac by lining the interior surfaces of the abdominal wall (anterior and lateral), by forming the boundary to the retroperitoneum (posterior), by covering the extraperitoneal structures in the pelvis (inferior), and by covering the undersurface of the diaphragm (superior). This parietal layer of the peritoneum reflects onto the abdominal visceral organs to form the visceral peritoneum. It thereby creates a potential space between the 2 layers (i.e., the peritoneal cavity).

The peritoneum consists of a single layer of flattened mesothelial cells over loose areolar tissue. The loose connective tissue layer contains a rich network of vascular and lymphatic capillaries, nerve endings, and immune-competent cells, particularly lymphocytes and macrophages. The peritoneal surface cells are joined by junctional complexes, thus forming a dialyzing membrane that allows passage of fluid and certain small solutes. Pinocytotic activity of the mesothelial cells and phagocytosis by macrophages allow for clearance of macromolecules.

Normally, the amount of peritoneal fluid present is less than 50 mL, and only small volumes are transferred across the considerable surface area in a steady state each day. The peritoneal fluid represents a plasma ultrafiltrate, with electrolyte and solute concentrations similar to that of neighboring interstitial spaces and a protein content of less than 30 g/L, mainly albumin. In addition, peritoneal fluid contains small numbers of desquamated mesothelial cells and various numbers and morphologies of migrating immune cells (reference range is < 300 cells/mL, predominantly of mononuclear morphology).

The organs are divided into:

- intraperitoneal (stomach, small bowel, colon, sigmoid colon);
- mesoperitoneal (liver, ascending and descending colon);
- extraperitoneal.

Functions of peritoneum

1. *Protection.* Attachments of protection are:

- mechanical;
- cellular immunity;
- humoral immunity;
- greater omentum often covers wound, organ perforation, place of perforation;
- peritoneal exudation has antibacterial properties.

1. 2. *Exudatio.*
2. 3. *Resorbition.*
3. 4. *Interoreception.*

Parietal peritoneum is innervated by intercostal nerves. After irritation of parietal peritoneum visceromotor reflex has appeared. As a result patient has local pain and mussel's tenderness.

Visceral peritoneum is innervated by sympatic and parasympatic nerves. Therefore visceral pain isn't localized. Doctors have to remember, that inflammation of pelvic peritoneum (it doesn't have somatic innervations) isn't accompanied with mussel's tenderness.

5. *Plastic function.* After traumatic injury or starting of inflammation layers of fibrin have formed. They confine infection.

Classifications

The first classification of peritonitis was suggested by Miculich (1886): 1) septic, 2) purulent, 3) progressive fibrino - purulent, 4) local. In 1912 Grekov defined the phases of peritonitis: early (1 - 2 days), late (3 - 5 days), final (6 - 21 days).

Modern classification of acute peritonitis

(Shalimov A.A., 1981)

According to origin

A) *Primary.* It occurs in the absence of an apparent intra-abdominal source of infection and is observed almost exclusively in patients with ascites formation from chronic liver disease.

B) *Secondary.* The common etiologic entities of secondary peritonitis include: esophagus Boerhaave syndrome (spontaneous rupture), malignancy, trauma, iatrogenic, peptic ulcer perforation, cholecystitis, acute pancreatitis, bowel perforation, ischemic bowel, strangulated hernia, bowel obstruction, diverticulitis, ulcerative colitis and Crohn disease, appendicitis.

According to etiology

A) Microflora of the digestive tract (E. coli, Enterococcus, Pseudomonas, Proteus, Streptococcus, Staphylococcus, Anaerobic infection).

B) Microflora non-connected with the digestive tract (tuberculous infection, gonococcal infection).

C) Aseptic (pancreatogenic, bilious).

D) Carcinomatous.

E) Parasitogenic.

According to cause

- A) Traumatic.
- B) Postoperative.
- C) Inflammatory.
- D) Perforated.

According to character of exudate

- A) Serous.
- B) Serofibrinous.
- C) Fibrinous.
- D) Fibrinopurulent.
- E) Purulent.
- F) Putrefactive.

According to spreading of infection

- A) Local (inflammatory process is localized only in 1 anatomy region).
- B) Diffuse (inflammatory process is localized in 2 - 5 anatomy regions).
- C) Total (inflammatory process is localized in 6 - 9 anatomy regions).

Phases of peritonitis

- A) Reactive (< 24 hours).
- B) Toxic (24 - 72 hours).
- C) Terminal (>72 hours).

Pathophysiology

Peritonitis is a serious manifestation of the surgical infection. The leading parts are: a) pathogenic microflora; b) intoxication; c) hypovolemia; d) deep metabolic disturbances.

The first phase - reactive phase

1. 1. From the moment the aggressive factor has gotten into abdominal cavity, the signs of inflammation (edema, hyperemia, and exudation) start.
2. 10 minutes - appearance of exudate into abdominal cavity.
3. 2 hours - formation of adhesions between peritoneum, bowels and large omentum starts.
4. 18 hours - formation of friable mass has been completed.
5. 2. Activation of function of hypothalamo-pituitary-adrenal axis.
6. 3. Activation of biologically active substances: kinins, biogenic amines. They control blood circulation and intestinal motor function.
7. 4. Activation of immune response.
8. 5. Starting of disturbances of microcirculation.
9. 6. Development of adynamic ileus. But barrier function of bowel wall is survived.

The first phase - reactive phase

1. The leading factor at this stage is intoxication. Exactly intoxication usually determines the result of treatment. The constituents of intoxication are:

- peritoneal exudate which is absorbed;
- microflora (exo- end endotoxins);
- proteolytic enzymes, which are released after destruction of leucocytes (cathepsins);
- toxic substances, which are produced and absorbed into peritoneal cavity (phenols, skatoles).

1. Adynamic ileus. Distended bowel wall loses barrier function and translocation of microorganisms starts. Free liquid is collected into intestinal lumen- "sequestration of liquid into the third space" (transudate, digestive juice).
2. The organism can't limit the infection and inflammatory process spreads into all abdominal cavity.
3. Immune response is depressed.

The third phase - terminal phase

This is a stage of septic shock and multiple organ failure. The changes are irreversible. Intoxication,

disturbances of metabolism and hemodynamic are fatal.

Toxic hepatitis. Liver is the first organ which gets toxic substances per portal vein system. Liver metabolic disorders start: protein and pigmental metabolism, function of disintoxication is decreasing.

Toxic nephropathy: proteinuria, microhematuria, azotemia.

Toxic myocardiodystrophy: hollowness of tones, tachycardia, extrasystole, ST segment depression.

Toxic alteration of lungs: respiratory distress syndrome ("shock lung").

Clinical diagnostic of acute peritonitis

Clinical manifestations of acute peritonitis depend on:

- disease which causes the peritonitis;
- stage of peritonitis;
- spreading of peritonitis;
- characteristics of microflora;
- activity of immune response.

The diagnosis of peritonitis is usually clinical. Essentially, all patients present with some degree of abdominal pain. This pain may be acute or more insidious in onset. Initially, the pain is often dull and poorly localized (visceral peritoneum) and then progresses to steady, severe, and more localized pain (parietal peritoneum). If the infectious process is not contained, the pain becomes diffuse. In certain disease entities (e.g., gastric perforation, severe acute pancreatitis, intestinal ischemia), the abdominal pain may be generalized from the beginning.

Anorexia and nausea are frequently present. Vomiting may occur because of the underlying visceral organ pathology or secondary to the peritoneal irritation.

On physical examination, patients with peritonitis most often appear unwell and in acute distress. Fever with temperatures that can exceed 38°C is usually present, but patients with severe sepsis may present with hypothermia. Tachycardia is caused by the release of inflammatory mediators and intravascular hypovolemia caused by anorexia and vomiting, fever, and third-space losses into the peritoneal cavity and bowels. With progressive dehydration, patients may become hypotensive, they may demonstrate decreased urine output, and, with severe peritonitis, they may present septic shock.

On abdominal examination, essentially all patients demonstrate tenderness to palpation. In most patients (even with generalized peritonitis and severe diffuse abdominal pain), the point of maximal tenderness roughly overlies the pathologic process (i.e., the site of maximal peritoneal irritation). Patients with severe peritonitis often avoid all motion and keep their hips flexed to relieve the abdominal wall tension.

The abdomen is often distended, with hypoactive-to-absent bowel sounds. This finding reflects a generalized ileus and may not be present if the infection is well localized.

Occasionally, the abdominal examination reveals an inflammatory mass. Examining the abdomen of a patient with peritonitis and mass, the patient should be supine to left lateral position for better relaxation of the abdominal wall.

Rectal examination often elicits increased abdominal pain, particularly with inflammation of the pelvic organs but rarely indicates a specific diagnosis. A tender inflammatory mass toward the right may indicate appendicitis, and anterior fullness and fluctuation may indicate a pelvic abscess. In female patients, vaginal and bimanual examination may lead to the differential diagnosis of pelvic inflammatory disease.

A complete physical examination is important. Thoracic processes with diaphragmatic irritation (e.g., empyema), extraperitoneal processes (e.g., pyelonephritis, cystitis, acute urinary retention), and abdominal wall processes (e.g., infection, rectus hematoma) may mimic certain signs and symptoms of peritonitis. Always examine the patient carefully for the presence of external hernias to rule out intestinal incarceration.

Remember that the presentation and the findings on clinical examination may be entirely inconclusive or unreliable in patients with significant immunosuppression (e.g., severe diabetes, steroid use, posttransplant status, HIV), in patients with altered mental state (e.g., head injury, toxic encephalopathy, septic shock, analgesic agents), in patients with paraplegia, and in patients of advanced age.

Lab. studies

CBC with differential, serum electrolytes with renal function. Most patients with intra-abdominal infections demonstrate leukocytosis (>11,000 cells/mL) with a shift to the immature forms on the differential cell count. Patients in severe sepsis, patients who are immunocompromised, and patients with certain types of infections (e.g., fungal, cytomegaloviral) may demonstrate absence of leukocytosis or leucopenia.

Blood chemistry may reveal dehydration and acidosis.

Liver function tests if clinically indicated.

Amylase and lipase if pancreatitis is suspected.

Urinalysis (UA) is essential to rule out urinary tract diseases (e.g., pyelonephritis, renal stone disease); however, patients with lower abdominal and pelvic infections often demonstrate WBC in the urine and microhematuria.

In patients with diarrhea, evaluate a stool for specific culture (i.e., Salmonella, Shigella, cytomegalovirus) if the patient's history suggests infectious enterocolitis.

Aerobic and anaerobic blood cultures.

Peritoneal fluid evaluation (i.e., paracentesis, aspiration of abdominal fluid collections, intraoperative peritoneal fluid cultures).

When assessing a peritoneal fluid sample for peritoneal infection, evaluate the sample for pH, glucose, protein, lactate dehydrogenase, cell count, Gram stain, and aerobic and anaerobic cultures, a peritoneal fluid amylase.

Imaging studies

Radiographs. Plain films of the abdomen (e.g., supine, upright, and lateral decubitus positions) are often the first imaging studies obtained in patients presenting with peritonitis. Their value in reaching a specific diagnosis is limited.

Free air is present in most cases of anterior gastric and duodenal perforation but is much less frequent with perforations of the small bowel and colon. Remember that the presence of free air is not mandatory with visceral perforation and that small amounts of free air are missed easily on plain films.

Ultrasound. Abdominal ultrasound may be helpful in the evaluation of right upper quadrant (e.g., perihepatic abscess, cholecystitis, biloma, pancreatitis, pancreatic pseudocyst), right lower quadrant, and pelvic pathology (e.g., appendicitis, tubo-ovarian abscess, Douglas pouch abscess), but the examination is sometimes limited because of patient discomfort, abdominal distension, and bowel gas interference.

Ultrasonography may detect increased amounts of peritoneal fluid, but its ability to detect quantities of less than 100 mL is limited. The central (perimesenteric) peritoneal cavity is not visualized well with transabdominal ultrasonography. Examination from the flank or back may improve the diagnostic yield,

and providing the ultrasonographer with specific information of the patient's condition and the suspected diagnosis before the examination is important. With an experienced ultrasonographer, a diagnostic accuracy of greater than 85% has been reported in several series.

Over the past several years, ultrasound-guided aspiration and placement of drains has evolved into a valuable tool in the diagnosis and treatment of abdominal fluid collections.

Computed tomography scans of the abdomen and pelvis remain the diagnostic study of choice for peritoneal abscess and the related visceral pathology. CT scan is indicated in all cases where the diagnosis cannot be established on clinical grounds and findings on abdominal plain films. Whenever possible, the CT scan should be performed with enteral and intravenous contrast. CT scans can detect small quantities of fluid, areas of inflammation and other GI tract pathology, with sensitivities that approach 100%.

Peritoneal abscesses and other fluid collections may be aspirated for diagnosis and drained under CT guidance.

Nuclear medicine scans (e.g., gallium Ga 67 scan, indium In 111-labeled autologous leucocyte scan, technetium Tc 99m-iminoacetic acid derivative scan).

These diagnostic studies have little use in the initial evaluation of patients with suspected peritonitis or intra-abdominal sepsis. They are most frequently used in the evaluation of fever of unknown origin or in patients with persistent fever despite adequate antibiotic treatment and negative CT scan findings.

Magnetic resonance imaging is an emerging imaging modality for the diagnosis of suspected intra-abdominal abscesses.

Contrast studies. Conventional contrast studies (i.e., upper gastrointestinal tract and colorectal contrast enema, fistulogram, contrast studies of drains and stents) are reserved for specific indications in the setting of suspected peritonitis or peritoneal abscess.

Medical therapy

The general principles guiding the treatment of intra-abdominal infections are 4-fold:

1. 1) to control the infectious source;
2. 2) to eliminate bacteria and toxins;
3. 3) to maintain organ system function;
4. 4) to control the inflammatory process.

Medical, nonoperative interventional, and operative treatment options are complimentary, not competitive, in the treatment of peritoneal infections.

Medical support includes:

1. 1) systemic antibiotic therapy;
2. 2) intensive care with hemodynamic, pulmonary, and renal replacement support;
3. 3) nutrition and metabolic support;
4. 4) inflammatory response modulation therapy.

Treatment of peritonitis and intra-abdominal sepsis always begins with volume resuscitation, correction of potential electrolyte and coagulation abnormalities, and empiric broad-spectrum parenteral antibiotic coverage.

Antibiotic therapy. It is based on culture results.

Third-generation cephalosporin:

Gram-negative E coli

Enterobacter species

Klebsiella species

Proteus species

Second-generation cephalosporin, Penicillins with anaerobic activity, Quinolones with anaerobic activity, Quinolone and metronidazole, Aminoglycoside and metronidazole:

Gram-positive Streptococcus species

Enterococcus species
 Anaerobic Bacteroides fragilis
 Other Bacteroides species
 Eubacterium species
 Clostridium species
 Anaerobic Streptococcus species
 Tertiary Gram-negative Enterobacter species
 Pseudomonas species
 Enterococcus species
 Second-generation cephalosporin
Carbapenems.
Triazoles or amphotericin (considered in fungal etiology).

Several studies suggest that antibiotic therapy is not as effective in later stages of the infection and that early (preoperative) systemic antibiotic therapy can result in significant reduction of concentration and growth rates of viable bacteria in the peritoneal fluid. Therefore, begin empiric therapy as soon as the diagnosis of peritoneal infection is suspected. The initial therapy for acute peritonitis must be mainly active against gram-negative organisms (*E. coli*, Enterobacteriaceae species) and anaerobes (e.g., *B. fragilis*).

In severe and hospital-acquired intra-abdominal infections, imipenem, piperacillin/tazobactam, and a combination of aminoglycosides and metronidazole are often effective.

Carbapenem is effective compared to piperacillin or tazobactam in the treatment of complicated intra-abdominal infection and was well tolerated.

Additional clinical antimicrobial studies are underway investigating the efficacy of new quinolones in the treatment of intra-abdominal infection.

The optimal duration of antibiotic therapy must be individualized and depends on the underlying pathology, severity of infection, speed and effectiveness of source control, and the patient response to therapy.

In uncomplicated peritonitis with early adequate source control, a course of 5-7 days is adequate in most cases. Complicated persistent infections and infections in patients who are immunocompromised may warrant a prolonged course of antibiotic therapy.

Some patients demonstrate persistent signs of inflammation without a defined infectious focus. In these patients, continued broad-spectrum antibiotic therapy may be more useful.

Nonoperative drainage. Today, abundant literature documents the safety and efficacy of ultrasound- and CT-guided percutaneous drainage of abdominal and extraperitoneal abscesses.

Common reasons for failure of primary nonoperative management include enteric fistula (e.g., anastomotic dehiscence), pancreatic involvement, infected clot, and multiple or multilocated abscesses.

In peritoneal abscess formation caused by subacute bowel perforation (e.g., diverticulitis, Crohn disease, appendicitis), primary percutaneous management with percutaneous drainage was successful in most patients.

Surgical treatment

Surgery remains an important therapeutic modality for all cases of peritoneal infection. Any operation should address the first 2 principles of the treatment of intra-peritoneal infections: early and definitive source control and elimination of bacteria and toxins from the abdominal cavity.

The operative approach is directed by the underlying disease process and the type and severity of the intra-abdominal infection. The surgeon should always strive to arrive at a specific diagnosis and delineate the intra-abdominal anatomy as accurately as possible prior to the operation.

However, in severe abdominal sepsis, a delay of operative management may lead to a significantly higher need for reoperations and overall worse outcomes; early exploration may be indicated.

Open-abdomen technique and scheduled reoperation

In certain situations, staging the operative approach to intraperitoneal infections is appropriate. Staging may be performed as a scheduled second-look operation or through open management, with or without temporary closure (laparostomy).

Second-look operations may be used in a damage control fashion. In these cases, the patient at initial operation is severely ill and unstable from septic shock or coagulopathy (e.g., mediator liberation, disseminated intravascular coagulation). The goal of the initial operation is to provide preliminary drainage and to remove obviously necrotic tissue.

Then, the patient is resuscitated and stabilized for 24-36 hours and returned to the operating room for a more definitive drainage and source control.

In conditions related to bowel ischemia, the initial operation aims to remove all frankly devitalized bowel. The second-look operation serves to reevaluate for further demarcation and decision-making regarding reanastomosis or diversion.

In severe peritonitis, particularly with extensive retroperitoneal involvement (e.g., necrotizing pancreatitis), open treatment with repeat reexploration, debridement and intraperitoneal lavage has been shown to be effective.

Temporary closure of the abdomen to prevent herniation and contamination from the outside of the abdominal contents can be achieved using gauze and large, impermeable, self-adhesive membrane dressings, mesh (e.g., Vicryl, Dexon), nonabsorbable mesh (GORE-TEX, polypropylene) with or without zipper or Velcrol-like closure devices, and vacuum-assisted closure (VAC) devices. Advantages of this management strategy include avoidance of abdominal compartment syndrome (ACS) and easy access for reexploration. The disadvantages include significant disruption of respiratory mechanics and potential contamination of the abdomen with nosocomial pathogens.

Gastrointestinal decompression. It is indicated in patients with severe peritonitis and ileus. It is achieved by transnasal, transstomal or transanal small or/and large bowel tube. The aims of procedure are:

- removing of toxic bowel content;
- stabilization of bowel motor function;
- enteral nutritional supporting;
- prevention of postoperative adhesion bowel obstruction.

Laparoscopy

Laparoscopy is gaining wider acceptance in the diagnosis and treatment of abdominal infections. Initial laparoscopic examination of the abdomen can assist in determination of the etiology of peritonitis. Laparoscopic diagnosis and peritoneal lavage in patients with peritonitis secondary to diverticulitis without fecal peritoneal contamination has helped to avoid operation in most patients in small clinical trials.

Successful laparoscopic repair of perforated gastric and duodenal ulcers has also been reported.

The treatment of perihepatic infections via laparoscopic approach has been well established in acute cholecystitis, where laparoscopic cholecystectomy has become the mainstay of therapy. More recently, primary treatment of subphrenic abscesses and laparoscopic ultrasound-assisted drainage of pyogenic liver abscesses have been performed successfully.

Individual reports also describe successful drainage of peripancreatic fluid collections and complicated intra-abdominal abscesses that are not amenable to CT scan - or ultrasound-guided percutaneous drainage.

As minimally invasive procedures continue to advance technologically, use of these approaches is likely to increase, reducing the need for the open surgical approach for peritoneal abscess drainage.

Preoperative details

Volume resuscitation and prevention of secondary organ system dysfunction are of utmost importance in the treatment of patients with intra-abdominal infections. Depending on the severity of the disease, these patients should have Foley catheters placed to monitor urine output. Use invasive hemodynamic monitoring in severely ill patients to guide volume resuscitation and inotropic support. Correct existing serum electrolyte disturbances and coagulation abnormalities as best as possible before any intervention.

Begin empiric broad-spectrum systemic antibiotic therapy as soon as the diagnosis of intra-abdominal infection is suspected. Remember that patients with peritonitis often have severe abdominal pain. Provide adequate analgesia with parenteral narcotic agents as soon as possible. In the setting of significant nausea, vomiting, or abdominal distension caused by obstruction or ileus, institute nasogastric decompression as soon as possible. Consider intubation and ventilator support early in patients with evidence of septic shock or altered mental status to prevent further decompensation.

In patients with severe infections and certain disease processes (e.g., necrotizing pancreatitis, bowel ischemia), informed consent should include the potential need for several reoperations and enteric diversion. The involved physicians and surgeon should not downplay the significant morbidities associated with abdominal sepsis when discussing these issues with the patient and/or family.

Intraoperative details

A vertical midline incision is the incision of choice in most patients with generalized peritonitis because it allows access to the entire peritoneal cavity. In patients with localized peritonitis (e.g., acute

appendicitis, cholecystitis), an incision directly over the site of pathology (e.g., right lower quadrant, right subcostal) is usually adequate.

In patients with an unclear etiology of the peritonitis, initial diagnostic laparoscopy may be useful.

The intra-abdominal anatomy may be significantly distorted because of inflammatory masses and adhesions. Normal tissue planes and boundaries may be obliterated. The inflamed organs are often very friable, and the surgeon must exercise great caution when exploring the patient with peritoneal infection.

Hemodynamic instability may occur at any time during treatment because of bacteremia and cytokine release. Patients often demonstrate significant fluid shifts with third spacing. Swelling of the bowel, retroperitoneum, and abdominal wall may preclude safe abdominal closure after prolonged cases in patients who are severely ill.

Inflammation causes regional hyperemia, and sepsis may cause coagulation deficits and platelet dysfunction, leading to increased bleeding. Careful dissection and meticulous hemostasis are of utmost importance.

One of the critical decisions in the surgical treatment of patients with severe peritonitis is regarding whether to use a closed-abdomen or open-abdomen technique. The goal of the closed-abdomen technique is to provide definitive surgical treatment at the initial operation; perform primary fascial closure and perform repeat laparotomy only when clinically indicated. The goal of the open-abdomen technique is to provide easy direct access to the affected area. Source control is achieved through repeated reoperations or open packing of the abdomen. This technique may be well suited for initial damage control in extensive peritonitis. Also consider patients who are at high risk for development of abdominal compartment syndrome (e.g., intestinal distension, extensive abdominal wall and intra-abdominal organ edema) for this technique because attempts to perform primary fascial closure under significant tension in these circumstances are associated with an increased incidence of multiorgan failure (e.g., renal, respiratory), necrotizing abdominal wall infections, and mortality.

Postoperative details

Postoperatively, monitor all patients closely in the appropriate clinical setting for adequacy of volume resuscitation, resolution or persistence of sepsis, and the development of organ system failure. Appropriate systemic broad-spectrum antibiotic coverage must be continued without interruption for the appropriate time.

The patient's overall condition should improve significantly and progressively within 24-72 hours of the initial treatment (i.e., resolution of the signs and symptoms of infection, mobilization of interstitial fluid). This time course may be prolonged in patients who are critically ill with significant multiple organ system dysfunction. A lack of improvement should prompt an aggressive search for a persistent or recurrent intraperitoneal or new extraperitoneal infectious focus.

Patients requiring surgical intervention for peritonitis demonstrate a significantly increased risk for surgical site infections and wound healing failure; monitor patients closely for this potential complication.

All patients who are critically ill and patients receiving prolonged antibiotic therapy are at increased risk for developing secondary opportunistic infections (e.g., fungal infections, central venous catheter infections, ventilator-associated pneumonia); monitor patients closely for signs and symptoms of these complications.

Nutrition. In general, patients with peritonitis develop some degree of gut dysfunction (ileus) after exploration. If enteral feeding is contraindicated or not tolerated, parenteral nutrition should be instituted.

Follow-up care

After resolution of peritonitis and peritoneal abscesses, follow-up care is directed mostly by specifics of the underlying disease process and the presence or absence of chronic complications (e.g., enterocutaneous fistulae). Patients with simple peritoneal infections after appendicitis or cholecystitis are usually cured and do not require long-term follow-up care. Patients with peritoneal operations for perforated peptic ulcer disease, Crohn disease, pancreatitis, and others often require lifelong medical therapy and treatment of recurrent complications.

Chapter 8 Hernias of abdominal wall

Hernia of the abdominal wall or external hernia is such surgical disease, which is characterized by protrusion of the visceral organs from the place of their physiological placement through the natural canals or defects of the abdominal and pelvic wall. Uncomplicated abdominal wall hernias do well. However, hernias with associated strangulation have an associated mortality rate of 10%.

Etiology of hernias

Hernias are divided into two main groups:

- congenital;
- acquired.

Contributes factors: weakness of the abdominal wall (anatomical; congenital; connected with sex, age, weight loss, injury, postoperative scar, pregnancy).

Causes factors: increased abdominal pressure (hard physical activity, chronic cough, chronic constipation, obstructive uropathy and ascites).

Pathomorphology

Each abdominal hernia consists of hernia's orifice, hernia's sac and hernia's contents. Hernia's sac is formed by the parietal peritoneum and can contain any organ from abdominal cavity, but mostly - small intestine and omentum. Sometimes it contains other organs: large intestine, urinary bladder, ovary and appendix.

The main parts of the hernia pouch are neck, body and fundus. Through the hernia's orifice peritoneum is protruding. The sliding hernia occurs when the hernia's sac is partially formed by the wall of an organ without peritoneal covering (e.g., posterior cecum, ovary, bladder, sigmoid).

Classification

1. According to the anatomical localization:

- inguinal (indirect and direct) hernia;
- midline hernia;

- femoral hernia;
- umbilical hernia;
- lumbar hernia;
- obturator hernia;
- ischiorectal hernia.

2. According to the clinical presentations:

- complete and incomplete;
- reducible (when the contents of the hernia sac can be returned to their normal anatomic domain) and nonreducible;
- traumatic;
- postoperative;
- complicated and noncomplicated.

Hernia's complications

- incarceration;
- strangulation;
- contain's inflammation;
- contain's trauma;
- contain's malignization.

Abdominal wall anatomy

The skin of the lower anterior abdominal wall is innervated by anterior and lateral cutaneous branches of the ventral rami of the seventh through 12th intercostal nerves and by the ventral rami of the first and second lumbar nerves. These nerves course between the lateral flat muscles of the abdominal wall and enter the skin through the subcutaneous tissue.

The first layers encountered beneath the skin are Camperis and Scarpais fasciae in the subcutaneous tissue. The only significance of these layers is that when sufficiently developed, they can be reapproximated to provide another layer between a repaired inguinal floor and the outside. The major blood vessels of this superficial fatty layer are the superficial inferior and superior epigastric vessels, the intercostals vessels, and the superficial circumflex iliac vessels (which are branches of the femoral vessels).

The external oblique muscle is the most superficial of the great flat muscles of the abdominal wall. This muscle arises from the posterior aspects of the lower eight ribs and interdigitates with both the serratus anterior and the latissimus dorsi at its origin. The posterior portion of the external oblique muscle is oriented vertically and inserts on the crest of the ileum. The anterior portion of the muscle courses inferiorly and obliquely toward the midline and the pubis. The muscle fibers themselves are of no interest to the inguinal hernia surgeon until they give way to form its aponeurosis, which occurs well above the inguinal region. The obliquely arranged anterior inferior fibers of the aponeurosis of the external oblique muscle fold back on themselves to form the inguinal ligament, which attaches laterally to the anterior superior iliac spine. In most persons, the medial insertion of the inguinal ligament is dual: one portion of the ligament inserts on the pubic tubercle and the pubic bone, whereas the other portion is fan-shaped and spans the distance between the inguinal ligament proper and the pectineal line of the pubis. This fan-shaped portion of the inguinal ligament is called the lacunar ligament. It blends laterally with Cooperis ligament. The more medial fibers of the aponeurosis of the external oblique muscle divide into a medial crus and a lateral crus to form the external or superficial inguinal ring, through which the spermatic cord (or the round ligament) and branches of the ilioinguinal and genitofemoral nerves pass.

The rest of the medial fibers insert into the linea alba after contributing to the anterior portion of the rectus sheath.

Beneath the external oblique muscle is the internal abdominal oblique muscle. The fibers of the

internal abdominal oblique muscle fan out following the shape of the iliac crest, so that the superior fibers course obliquely upward toward the distal ends of the lower three or four ribs while the lower fibers orient themselves inferomedially toward the pubis to run parallel to the external oblique aponeurotic fibers. These fibers arch over the round ligament or the spermatic cord, forming the superficial part of the internal (deep) inguinal ring.

Beneath the internal oblique muscle is the transversus abdominis. This muscle arises from the inguinal ligament, the inner side of the iliac crest, the endoabdominal fascia, and the lower six costal cartilages and ribs, where it interdigitates with the lateral diaphragmatic fibers. The medial aponeurotic fibers of the transversus abdominis contribute to the rectus sheath and insert on the pecten ossis pubis and the crest of the pubis, forming the *faix inguinalis*. Infrequently, these fibers are joined by a portion of the internal oblique aponeurosis.

Aponeurotic fibers of the transversus abdominis also form the structure known as the aponeurotic arch. It is theorized that contraction of the transversus abdominis causes the arch to move downward toward the inguinal ligament, thereby constituting a form of shutter mechanism that reinforces the weakest area of the groin when intra-abdominal pressure is raised. The area beneath the arch varies. Many authorities believe that a high arch, resulting in a larger area from which the transversus abdominis is by definition absent, is a predisposing factor for a direct inguinal hernia. The transverse aponeurotic arch is also important because the term is used by many authors to describe the medial structure that is sewn to the inguinal ligament in many of the older inguinal hernia repairs.

The rectus abdominis forms the central anchoring muscle mass of the anterior abdomen. It arises from the fifth through seventh costal cartilages and inserts on the pubic symphysis and the pubic crest. It is innervated by the seventh through 12th intercostal nerves, which laterally pierce the aponeurotic sheath of the muscle. The semilunar line is the slight depression in the aponeurotic fibers coursing toward the muscle. In a minority of persons, the small pyramidalis muscle accompanies the rectus abdominis at its insertion. This muscle arises from the pubic symphysis. It lies within the rectus sheath and tapers to attach to the linea alba, which represents the conjunction of the two rectus sheaths and is the major site of insertion for three aponeuroses from all three lateral muscle layers. The line of Douglas (i.e., the arcuate line of the rectus sheath) is formed at a variable distance between the umbilicus and the inguinal space because the fasciae of the large flat muscles of the abdominal wall contribute their aponeuroses to the anterior surface of the muscle, leaving only transversalis fascia to cover the posterior surface of the rectus abdominis.

The innervation of the anterior wall muscles is multifaceted.

The seventh through 12th intercostal nerves and the first and second lumbar nerves provide most of the innervation of the lateral muscles, as well as of the rectus abdominis and the overlying skin. The nerves pass anteriorly in a plane between the internal oblique muscle and the transversus abdominis, eventually piercing the lateral aspect of the rectus sheath to innervate the muscle therein.

The external oblique muscle receives branches of the intercostal nerves, which penetrate the internal oblique muscle to reach it.

The anterior ends of the nerves form part of the cutaneous innervation of the abdominal wall. The first lumbar nerve divides into the ilioinguinal nerve and the iliohypogastric nerve.

These important nerves lie in the space between the internal oblique muscle and the external oblique aponeurosis. They may divide within the *psoas major* or between the internal oblique muscle and the transversus abdominis. The ilioinguinal nerve may communicate with the iliohypogastric nerve before innervating the internal oblique muscle. The ilioinguinal nerve then passes through the external inguinal ring to run parallel to the spermatic cord, while the iliohypogastric nerve pierces the external oblique muscle to innervate the skin above the pubis. The cremaster muscle fibers, which are derived from the internal oblique muscle, are innervated by the genitofemoral nerve. There can be considerable variability and overlap.

The blood supply of the lateral muscles of the anterior wall comes primarily from the lower three or four intercostal arteries, the deep circumflex iliac artery, and the lumbar arteries. The rectus abdominis has a complicated blood supply that derives from the superior epigastric artery (a terminal branch of the internal thoracic [internal mammary] artery), the inferior epigastric artery (a branch of the external iliac artery), and the lower intercostal arteries. The lower intercostal arteries enter the sides of the muscle after traveling between the oblique muscles; the superior and the inferior epigastric arteries enter the rectus sheath and anastomose near the umbilicus.

The endoabdominal fascia is the deep fascia covering the internal surface of the transversus abdominis, the iliacus, the *psoas major* and minor, the obturator internus, and portions of the periosteum. It is a continuous sheet that extends throughout the extraperitoneal space and is sometimes referred to as the wallpaper of the abdominal cavity.

The transversalis fascia is particularly important for inguinal hernia repair because it forms anatomic landmarks known as analogues or derivatives. The most significant of these analogues for hernia surgeons are the iliopectineal arch, the iliopubic tract, the crura of the deep inguinal ring, and Cooper's ligament.

The iliopubic tract is the thickened band of the transversalis fascia that courses parallel to the more

superficially located inguinal ligament. It is attached to the iliac crest laterally and inserts on the pubic tubercle medially. The insertion curves inferolaterally for 1 to 2 cm along the pectineal line of the pubis to blend with Cooper's ligament, ending at about the midportion of the superior pubic ramus. Cooper's ligament is actually a condensation of the periosteum and is not a true analogue of the transversalis fascia.

Hesselbach's inguinal triangle is the site of direct inguinal hernias. As viewed from the anterior aspect, the inguinal ligament forms the base of the triangle, the edge of the rectus abdominis forms the medial border, and the inferior epigastric vessels form the superolateral border.

Below the iliopubic tract are the critical anatomic elements from which a femoral hernia may develop. The iliopectineal arch separates the vascular compartment that contains the femoral vessels from the neuromuscular compartment that contains the iliopsoas muscle, the femoral nerve, and the lateral femoral cutaneous nerve. The vascular compartment is invested by the femoral sheath, which has three subcompartments: the lateral, containing the femoral artery and the femoral branch of the genitofemoral nerve; the middle, containing the femoral vein; and the medial, which is the cone-shaped cul-de-sac known as the femoral canal. The femoral canal is normally a 1 to 2 cm blind pouch that begins at the femoral ring and extends to the level of the fossa ovalis. The femoral ring is bordered by the superior pubic ramus inferiorly, the femoral vein laterally, and the iliopubic tract (with its curved insertion onto the pubic ramus) anteriorly and medially. The femoral canal normally contains preperitoneal fat, connective tissue, and lymph nodes (including Cloquet's node at the femoral ring), which collectively make up the femoral pad. This pad acts as a cushion for the femoral vein, allowing expansion such as might occur during a Valsalva maneuver, and serves as a plug to prevent abdominal contents from entering the thigh. A femoral hernia exists when the blind end of the femoral canal becomes an opening through which a peritoneal sac can protrude.

Between the transversalis fascia and the peritoneum is the preperitoneal space. In the midline behind the pubis, this space is known as the space of Retzius; laterally, it is referred to as the space of Bogros. The preperitoneal space is of particular importance for surgeons because many of the inguinal hernia repairs (see below) are performed in this area. The inferior epigastric vessels, the deep inferior epigastric vein, the iliopubic vein, the rectus vein, the retropubic vein, the communicating rectus-epigastric vein, the internal spermatic vessels, and the vas deferens are all encountered in this space.

Clinical sings

History and physical examination remain the best means of diagnosing hernias. The review of systems should carefully seek out associated conditions, such as ascites, constipation, obstructive uropathy, chronic obstructive pulmonary disease and cough.

Inguinal hernia. The diagnosis of hernia is usually made because a patient, parent, or physician sees a bulge in the inguinal region or scrotum. This bulge may be intermittent as the herniating viscus may or may not enter the space depending on intra-abdominal pressure.

In infants, the only symptom of a hernia may be increased irritability, especially with a large hernia. Hernias in older children and adults may be accompanied by a dull ache or burning pain, which often worsens with exercise or straining (e.g., coughing).

Examination of an adult is best performed from the seated position with the patient standing. One visualizes the inguinal canal areas for the bulge. Frequently, a provocative cough is necessary to expose the hernia. The cough is repeated as the examiner invaginates the scrotum and feels for an impulse. The diameter of the internal ring is assessed.

In a sliding inguinal hernia, a portion of viscus or its mesentery constitutes part of the hernia sac. The bladder can be seen medially in the hernia sac, while portions of the colon (cecum on the right side, sigmoid on the left side) may be part of any hernia sac. In females, the ovary or fallopian tubes may become part of the wall of the hernia sac and must be carefully preserved during repair.

If the visceral contents of a hernial sac do not easily reduce into the peritoneal cavity, the hernia is incarcerated. If the contents cannot be reduced at all, the hernia is irreducible. In chronic hernias, adhesions may impair reduction.

Some hernias, such as *obturator, femoral, or lumbar* hernias, should be considered as causes of

bowel obstruction. Intense pain is suggestive of strangulation with ischemic bowel. Torsion of the bowel on entry into the sac may lead to precipitous symptoms, while a more gradual onset of pain arises from progressive lymphatic, venous, and then finally arterial compromise secondary to occlusion at the neck of the sac.

Spigelian hernias present with local pain and signs of obstruction from incarceration. This pain increases with contraction of the abdominal musculature.

Interparietal hernias between the layers of the abdominal wall present in a similar manner. A mass may be just superior and lateral to the external ring, and the scrotum may not contain a testis.

Internal supravesical hernias may have obstructive symptoms of the intestinal tract or those resembling a urinary tract infection.

A *umbilical hernia* presents as a central, midabdominal bulge. Altered sensorium and obesity enhance the danger of incarceration. Hypertrophic, hyperpigmented, papyraceous skin is testimony to high pressure on the skin. The size of the fascial defect and whether it is circular provide management clues.

Diastasis recti or a widened linea alba has no clinical significance and does not require operative repair. However, there may be small openings in the linea alba through which preperitoneal fat can protrude. These *epigastric hernias* occur in children as well as in adults, suggesting that the defects are congenital.

The name *paraumbilical hernia* applies when this defect is adjacent to the umbilicus, while the term *epiplocele* or *ventral* hernia is used to describe more cranial defects. These midline hernias present as lumps anywhere along the linea alba and tend to cause sudden severe pain with exercise.

Clinical signs of hernia's strangulation:

- acute pain;
- incarceration;
- meteorism;
- vomiting.

SURGICAL TREATMENT

Inguinal herniorrhaphy. Nonprosthetic repair.

Local anesthesia is entirely adequate, especially when combined with intravenous infusion of a rapid-acting, short-lasting, amnesic and anxiolytic agent such as propofol. This is the approach most commonly employed in specialty hernia clinics.

The various inguinal herniorrhaphies have a number of initial technical steps in common.

Step 1. Initial incision.

Traditionally, the skin is opened by making an oblique incision between the anterior superior iliac spine and the pubic tubercle. For cosmetic reasons, however, many surgeons now prefer a more horizontal skin incision placed in the natural skin lines. In either case, the incision is deepened through Scarpais and Camperis fasciae and the subcutaneous tissue to expose the external oblique aponeurosis. The external oblique aponeurosis is then opened through the external inguinal ring.

Step 2. Mobilization of cord structures.

The superior flap of the external oblique fascia is dissected away from the anterior rectus sheath medially and the internal oblique muscle laterally. The iliohypogastric nerve is identified at this time; it can be either left in situ or freed from the surrounding tissue and isolated from the operative field by passing a hemostat under the nerve and grasping the upper flap of the external oblique aponeurosis. Routine division of the iliohypogastric nerve along with the ilioinguinal nerve is practiced by some surgeons but is not advised by most. The cord structures are then bluntly dissected away from the inferior flap of the external oblique aponeurosis to expose the shelving edge of the inguinal ligament and the iliopubic tract. The cord structures are lifted en masse with the fingers of one hand at the pubic tubercle so that the index finger can be passed underneath to meet the thumb or the fingers of the other hand. Mobilization of the cord structures is completed by means of blunt dissection, and a drain is placed around them for retraction during the procedure.

Step 3. Division of cremaster muscle.

Complete division of the cremaster muscle has been common practice, especially with indirect hernias. The purposes of this practice are to facilitate identification of the sac and to lengthen the cord for better visualization of the inguinal floor. Almost always, however, adequate exposure can be obtained by opening the muscle longitudinally, which reduces the chances of damage to the cord and prevents testicular descent. Accordingly, the latter approach should be considered best practice unless there are extenuating circumstances.

Step 4. High ligation of sac.

The term high ligation of the sac is used frequently in discussing hernia repair; its historical significance has ingrained it in the descriptions of most of the older operations. For our purposes in this chapter, high ligation of the sac should be considered equivalent to reduction of the sac into the preperitoneal space without excision. The two methods work equally well and are highly effective. Some surgeons believe that

sac inversion results in less pain (because the richly innervated peritoneum is not incised) and may be less likely to cause adhesive complications. Sac eversion in lieu of excision does protect intra-abdominal viscera in cases of unrecognized incarcerated sac contents or sliding hernia.

Step 5. Management of inguinal scrotal hernial sacs.

Some surgeons consider complete excision of all indirect inguinal hernial sacs important. The downside of this practice is that the incidence of ischemic orchitis from excessive trauma to the cord rises substantially. The logical sequel of ischemic orchitis is testicular atrophy, though this presumed relationship has not been conclusively proved. In our view, it is better to divide an indirect inguinal hernial sac in the mildportion of the inguinal canal once it is clear that the hernia is not sliding and no abdominal contents are present. The distal sac is not removed, but its anterior wall is opened as far distally as is convenient. Contrary to the opinion commonly voiced in the urologic literature, this approach does not result in excessive postoperative hydrocele formation.

Step 6. Repair of inguinal floor. Methods of repairing the inguinal floor differ significantly among the various repairs and are described separately.

Step 7. Relaxing incision.

A relaxing incision is made through the anterior rectus sheath and down to the rectus abdominis, extending superiorly from the pubic tubercle for a variable distance, as determined by the degree of tension present. Some surgeons prefer incision laterally at the superior end. This relaxing incision works because as the anterior rectus sheath separates, the various components of the abdominal wall are displaced laterally and inferiorly.

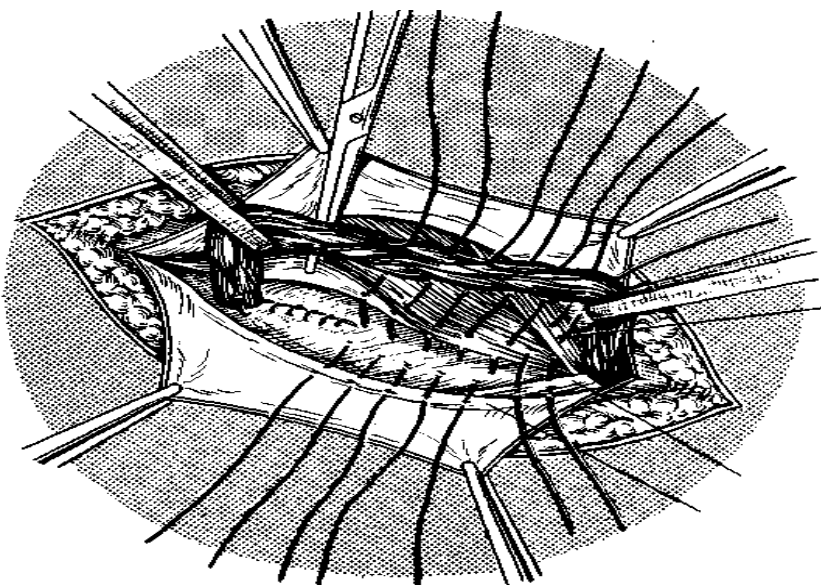
Step 8. Closure. Closure of the external oblique fascia serves to reconstruct the superficial (external) ring. The external ring must be loose enough to prevent strangulation of the cord structures yet tight enough to ensure that an inexperienced examiner will not confuse a dilated ring with a recurrence. A dilated external ring is sometimes referred to as an industrial hernia, because over the years it has occasionally been a problem during preemployment physical examinations. Scarpais fascia and the skin are closed to complete the operation.

Details of some specific repairs

Bassini repair (fig.23). Edoardo Bassini is considered the father of modern inguinal hernia surgery. The initial steps in the procedure have already described. Bassini felt that the incision in the external oblique aponeurosis should be as superior as possible while still so that the allowing the superficial external ring to be opened, reapproximation suture line created later in the operation would not be directly over the suture line of the inguinal floor reconstruction. Whether this technical point is significant is debatable.

Bassini also felt that lengthwise division of the cremaster muscle followed by resection was important for ensuring that an indirect hernial sac could not be missed and for achieving adequate exposure of the inguinal floor.

After performing the initial dissection and the reduction or ligation of the sac, Bassini began the reconstruction of the inguinal floor by opening the transversalis fascia from the internal inguinal ring to the pubic tubercle, thereby exposing the preperitoneal fat, which was bluntly dissected away from the undersurface of the superior flap of the transversalis fascia. This step allowed him to properly prepare the deepest structure in his famous "triple layer"



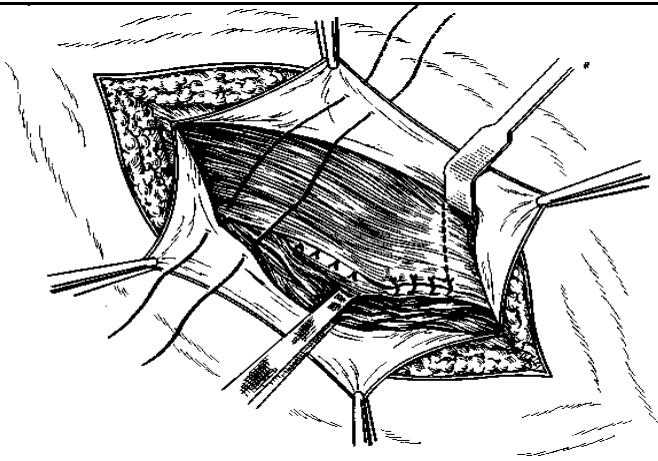


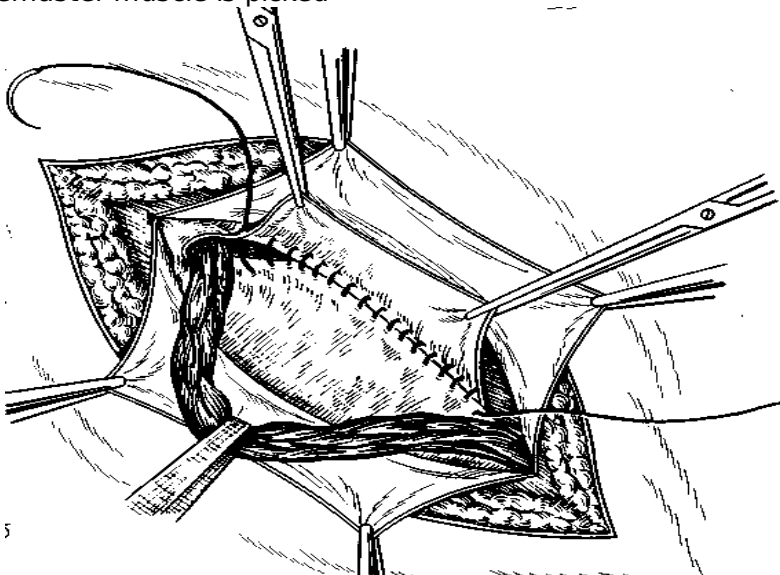
Figure 23. Inguinal herniorrhaphy: Bassini

repair.

The first stitch in Bassini's repair includes the triple layer superiorly and the periosteum of the medial side of the pubic tubercle, along with the rectus sheath. In current practice, however, most surgeons try to avoid the periosteum of the pubic tubercle so as to decrease the incidence of osteitis pubis. The repair is then continued laterally, and the triple layer is secured to the reflected inguinal ligament (Poupartis ligament) with nonabsorbable sutures. The sutures are continued until the internal ring is closed on its medial side. A relaxing incision was not part of Bassini's original description but now is commonly added.

Concerns about injuries to neurovascular structures in the preperitoneal space as well as to the bladder led many surgeons, especially in North America, to abandon the opening of the transversalis fascia. The unfortunate consequence of this decision is that the proper development of the triple layer is severely compromised. In lieu of opening the floor, a forceps (e.g., an Allis clamp) is used to grasp tissue blindly in the hope of including the transversalis fascia and the transversus abdominis. The layer is then sutured, along with the internal oblique muscle, to the reflected inguinal ligament as in the classic Bassini repair. The structure grasped in this modified procedure is sometimes referred to as the conjoined tendon, but this is not correct because of the variability in what is actually grasped in the clamp.

Shouldice repair (fig.24). The repair is started at the pubic tubercle by approximating the iliopubic tract laterally to the undersurface of the lateral edge of the rectus abdominis. The suture is continued laterally, approximating the iliopubic tract to the medial flap, which is made up of the transversalis fascia, the internal oblique muscle, and the transversus abdominis. Eventually, four suture lines are developed from the medial flap. The continuous suture is extended to the internal ring, where the lateral stump of the cremaster muscle is picked



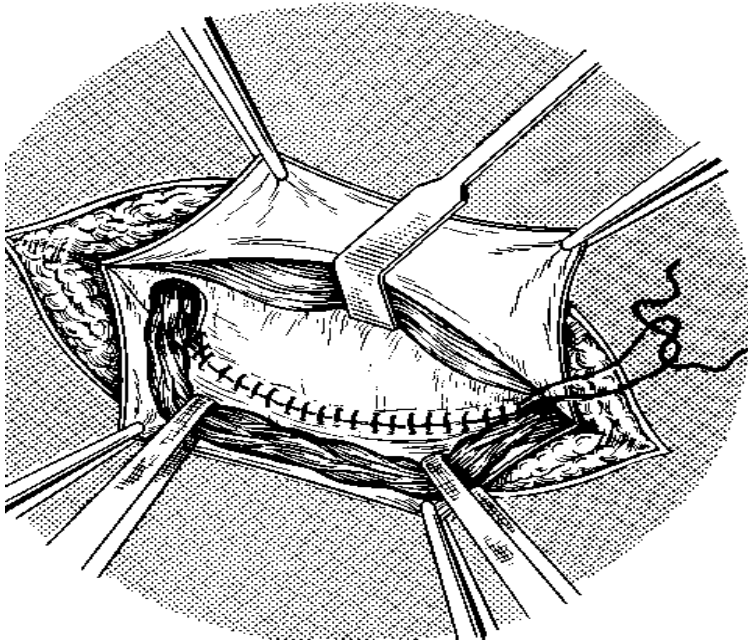


Figure 24. Inguinal herniorrhaphy: Shouldice repair.

up to form a new internal ring. Next, the direction of the suture is reversed back toward the pubic tubercle, approximating the medial edges of the internal oblique muscle and the transversus abdominis to Poupartis ligament, and the wire is tied to itself and then to the first knot. Thus, two suture lines are formed by the first suture. A second wire suture is started near the internal ring, approximating the internal oblique muscle and the transversus abdominis to a band of external oblique aponeurosis superficial and parallel to Poupartis ligament - in effect, creating a second, artificial Poupartis ligament. This third suture line ends at the pubic crest. The suture is then reversed, and a fourth suture line is constructed in a similar manner, superficial to the third line.

McVay Cooperis ligament repair. This operation is similar to the Bassini repair, except that it uses Cooperis ligament instead of the inguinal ligament for the medial portion of the repair.

Interrupted sutures are placed from the pubic tubercle laterally along Cooperis ligament, progressively narrowing the femoral ring; this constitutes the most common application of the repair - namely, treatment of a femoral hernia. The last stitch in Cooperis ligament is known as a transition stitch and includes the inguinal ligament. This stitch has two purposes: (1) to complete the narrowing of the femoral ring by approximating the inguinal ligament to Cooperis ligament, as well as to the medial tissue, and (2) to provide a smooth transition to the inguinal ligament over the femoral vessel so that the repair can be continued laterally (as in a Bassini repair). Given the considerable tension required to bridge such a large distance, a relaxing incision should always be used. In the view of many authorities, this tension results in more pain than is noted with other herniorrhaphies and predisposes to recurrence. For this reason, the McVay repair is rarely chosen today, except in patients with a femoral hernia or patients with a specific contraindication to mesh repair.

Girard repair. In these operations it is proposed to attach the edges of the internal oblique muscle and transverse muscle of abdomen to the inguinal ligament over the spermatic duct. The aponeurosis of the external oblique muscle sutured by second layer of the suture. Excess of the aponeurosis is fixed to the muscle in the form of duplication.

Spasokukotsky repair. Proposed to suture the edges of the internal oblique muscle and transverse muscle of abdomen with aponeurosis of the external oblique muscles by single-layer interrupted suture.

Martynov repair. Proposed the fixation to the Poupartis ligament the internal edge of the external oblique muscle aponeurosis without muscles. External edge of the aponeurosis is sutured over internal in the form of duplication.

Kimbarovsky repair. Based on the principles of joining similar tissues, proposed special suture: Sutures placed on 1 cm from the edge of the external oblique abdominal muscle aponeurosis, grasped the part of the internal oblique and transverse muscle of abdomen. After that, aponeurosis is sutured one more time from behind to the front and attached to the Poupartis ligament.

Kukudganov repair. Proposed to restore back wall of inguinal interval. Sutures are placed between the Couperis ligament, direct abdominal muscle and aponeurosis of the transversal muscle.

Postempsky repair (fig.25). Proposed the closure of inguinal interval with the lateralization moving of spermatic duct. The plastic narrowing of internal inguinal ring of to 0,8 cm is the important stage of this modification. On occasion, when internal and external inguinal rings are in one plane, the spermatic duct is displaced in lateral direction by transversal incision of the oblique and transversus muscles.

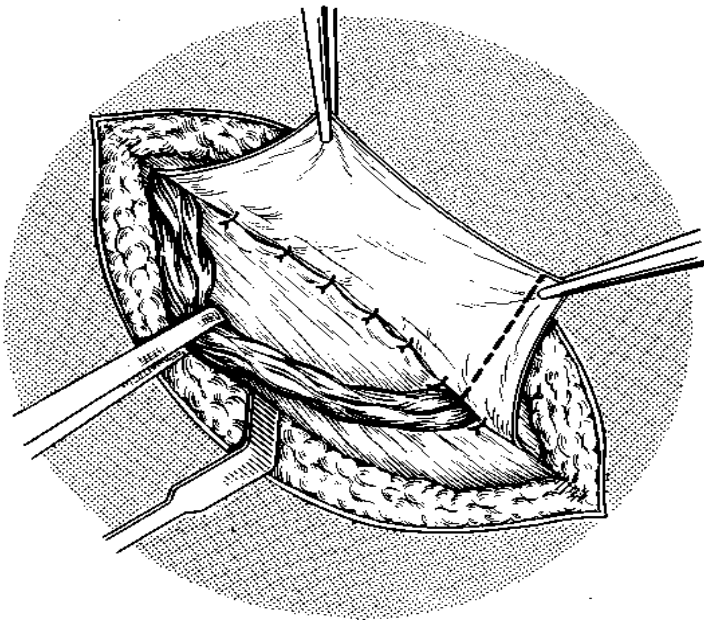


Figure 25. Inguinal herniorrhaphy: Postempsky repair.

Inguinal herniorrhaphy. Alloplastic repair.

Lichtenstein repair. The first five steps of a Lichtenstein repair are very similar to the first five steps of a conventional anterior nonprosthetic repair, but there are certain technical points that are worthy of emphasis. The external oblique aponeurosis is generously freed from the underlying anterior rectus sheath and internal oblique muscle and aponeurosis in an avascular plane from a point at least 2 cm medial to the pubic tubercle to the anterior superior iliac spine laterally. Blunt dissection is continued in this avascular plane from the area lateral to the internal ring to the pubic tubercle along the shelving edge of the inguinal ligament and the iliopubic tract. As a continuation of this same motion, the cord with its cremaster covering is swept off the pubic tubercle and separated from the inguinal floor. Besides mobilizing the cord, these maneuvers create a large space beneath the external oblique aponeurosis that can eventually be used for prosthesis placement. The ilioinguinal nerve, the external spermatic vessels and the genital branch of the genitofemoral nerve all remain with the cord structures.

For indirect hernias, the cremaster muscle is incised longitudinally, and the sac is dissected free and reduced into the preperitoneal space. Theoretically, this operation could be criticized on the grounds that if the inguinal floor is not opened, an occult femoral hernia might be overlooked. To date, however, an excessive incidence of missed femoral hernias has not been reported. In addition, it is possible to evaluate the femoral ring via the space of Bogro's through a small opening in the canal floor.

Direct hernias are separated from the cord and other surrounding structures and reduced back into the preperitoneal space. Dividing the superficial layers of the neck of the sac circumferentially - which, in effect, opens the inguinal floor - usually facilitates reduction and helps maintain it while the prosthesis is being placed. This opening in the inguinal floor also allows the surgeon to palpate for a femoral hernia. Sutures can be used to maintain reduction of the sac, but they have no real strength in this setting; their main purpose is to allow the repair to proceed without being hindered by continual extrusion of the sac into the field, especially when the patient strains.

Placement of prosthesis. A mesh prosthesis is positioned over the inguinal floor. For an adult, the prosthesis should be at least 15.8 cm. The medial end is rounded to correspond to the patient's particular anatomy and secured to the anterior rectus sheath at least 2 cm medial to the pubic tubercle. A

continuous suture of either nonabsorbable or long-lasting absorbable material should be used. Wide overlap of the pubic tubercle is important to prevent the pubic tubercle recurrences all too commonly seen with other operations. The suture is continued laterally in a locking fashion, securing the prosthesis to either side of the pubic tubercle (not into it) and then to the shelving edge of the inguinal ligament. The suture is tied at the internal ring.

Creation of shutter valve. A slit is made at the lateral end of the mesh in such a way as to create two tails, a wider one (approximately two thirds of the total width) above and a narrower one below. The tails are positioned around the cord structures and placed beneath the external oblique aponeurosis laterally to about the anterior superior iliac spine, with the upper tail placed on top of the lower. A single interrupted suture is placed to secure the lower edge of the superior tail to the lower edge of the inferior tail effect, creating a shutter valve. This step is considered crucial for preventing the indirect recurrences occasionally seen when the tails are simply reapproximated. The same suture incorporates the shelving edge of the inguinal ligament so as to create a domelike buckling effect over the direct space, thereby ensuring that there is no tension, especially when the patient assumes an upright position.

Securing of prosthesis. A few interrupted sutures are placed to attach the superior and medial aspects of the prosthesis to the underlying internal oblique muscle and rectus fascia. On occasion, the iliohypogastric nerve, which courses on top of the internal oblique muscle, penetrates the medial flap of the external oblique aponeurosis. In this situation, the prosthesis should be slit to accommodate the nerve. The prosthesis can be trimmed in situ, but care should be taken to maintain enough laxity to allow for the difference between the supine and the upright positions, as well as for possible shrinkage of the mesh.

Femoral herniorrhaphy.

There are some methods of surgical treatment of the femoral hernia, where the plastic repair is performed intraperitoneally from the side of thigh through the inguinal canal.

The Bassini method is attributed to "femoral". It is performed through an incision, that passes under inguinal fold. After removal of hernial sac the hernial opening is closed by suturing of lig. inguinal (1) to the pectineal ligament (2) without pressure of femoral vein (3) (*fig. 26*). The Rudgi-Parlavecho method (*fig. 27*). Ends of the transversus and internal oblique muscles and inguinal ligament sutured to the periosteum of pubic bone.

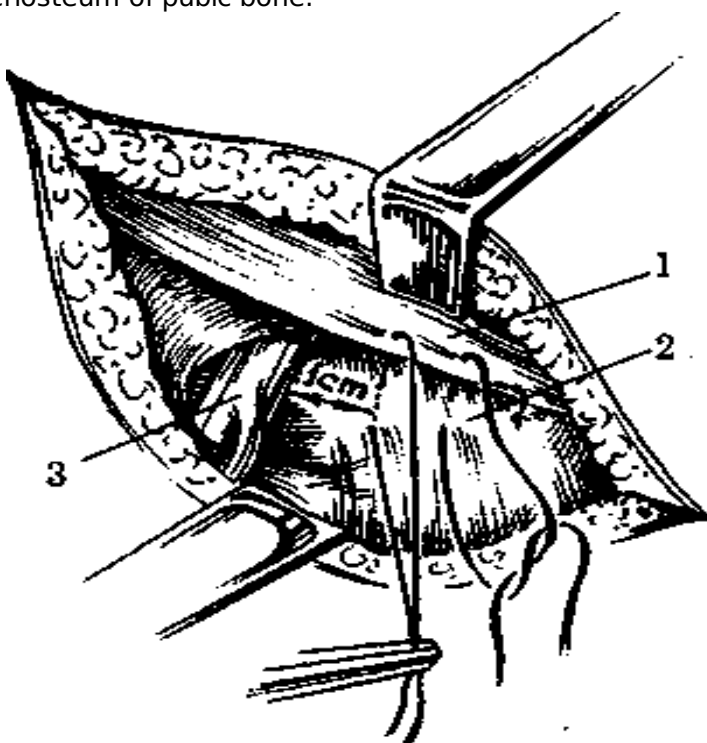


Figure 26. Bassini method.

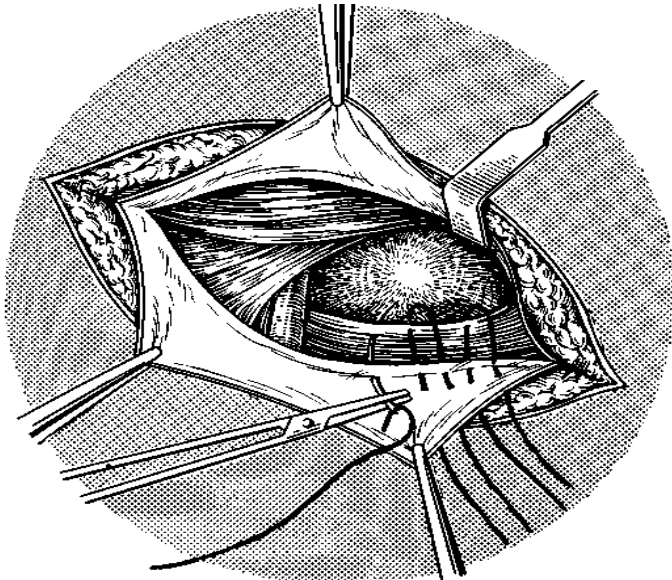


Figure 27. Rudji-Parlavecho method.

Umbilical and paraumbilical hernia

An umbilical hernia is the result of improper healing of an umbilical scar, which leads to a fascial defect that is covered by skin. If the defect is to one side, it is called a paraumbilical hernia; this variant is more common in adults. The vast majority of umbilical hernias presenting in children are congenital, whereas 90% of those diagnosed in adults are acquired. These hernias are eight times more common in black children than in white ones.

The onset of umbilical or paraumbilical hernia in older patients is usually sudden, and the defect tends to be relatively small. In these patients, it is important to look for an underlying cause of increased intra-

abdominal pressure (e.g., ascites or an intraabdominal tumor).

The differential diagnosis of an umbilical hernia should include so-called caput medusae, a condition in which varicosities extend radially from the umbilicus as a consequence of portal hypertension.

Another condition to be considered is the so-called Sister Mary Joseph node, which is a metastatic deposit of intra-abdominal cancer at the umbilicus. The cancer cells reach this area via lymphatic vessels in the falciform ligament.

Other periumbilical masses that might be confused with an umbilical hernia are umbilical granulomas, omphalomesenteric duct remnant cysts, and urachal cysts.

Most of the defects are small and can therefore be closed by simple suturing. Alternatively, the *Mayo* technique may be used (*fig.28*).

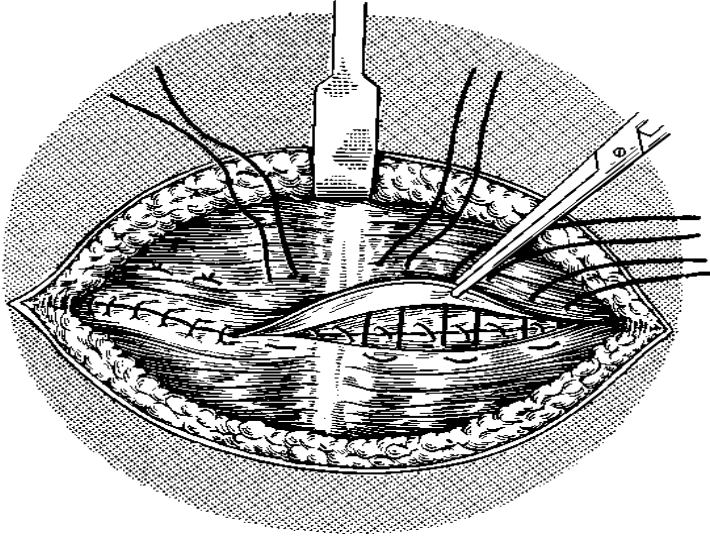


Figure 28. Mayo technique.

A subumbilical semilunar incision is made, the hernial sac is opened, the contents of the sac are reduced into the abdomen, and the sac is excised. An overlapping or waist-coating technique is then employed, in which the upper edge of the linea alba is placed so as to overlap the lower and fixed in place with a nonabsorbable mattress suture. This technique is controversial: some surgeons argue that the overlapping layers serve only to increase the tension on the repair, thus inviting recurrence.

The fascial defect is then bridged with prosthesis without fear of contact with the intra-abdominal viscera. The prosthesis is sutured circumferentially to the defect; alternatively, it can be sutured to the undersurface of the posterior rectus sheath and the linea alba above the peritoneal closure. If the peritoneum cannot be kept intact beneath the defect, omentum should be tacked to the peritoneum circumferentially to isolate the abdominal viscera from the prosthesis at least to some degree.

Postoperative hernia

Simple nonprosthetic repair.

Simple nonprosthetic repair of an incisional hernia is reserved for only the least complicated defects, because in large series of unselected patients, the recurrence rate ranges from 25% to 55%.

If there is a solitary defect 3 cm or less in diameter, primary closure with nonabsorbable suture material is appropriate.

Some surgeons use a Mayo "vest-over-pants" repair. Various advancement and darn procedures have also been described.

A more substantial repair for these defects was popularized by Ramirez. In this operation, known as the component separation technique, fascial planes are incised between muscle groups, so that, in effect, the abdominal wall is lengthened by allowing the muscle to separate on either side of a defect. The hernia can then be repaired primarily with less tension on the repair. This procedure is especially

useful at contaminated hernia sites.

A similar procedure is the keel operation of Maingot, which was popular in the middle of the 20th century. The anterior rectus sheath is incised longitudinally, and the medial edge is allowed to rotate behind the rectus abdominis. This, in effect, lengthens the posterior rectus sheath, allowing it to be closed under less tension. The lateral edges of the incised rectus sheath on each side are then approximated to each other.

Onlay prosthetic repair.

In this technique, a prosthetic onlay is placed over any of a wide variety of simple repairs. Large series of selected patients have documented acceptable results with onlay prosthetic repair, but most surgeons feel that this technique offers little advantage over the simple repair that the prosthesis overlies.

Prosthetic bridging repair.

Prosthetic bridging repair became popular in the 1990s, in keeping with the tension-free concept for inguinal herniorrhaphy.

When a hernia defect is bridged with a mesh prosthesis, every attempt should be made to isolate the material from the intraabdominal viscera to prevent erosion and subsequent fistula formation or adhesive bowel obstruction. This can be accomplished by means of a peritoneal flap constructed from the peritoneal sac or omentum. When contact with intra-abdominal organs cannot be avoided, expanded polytetrafluoroethylene (e-PTFE) should be strongly considered for the prosthesis. Most authorities feel that complications are less likely with e-PTFE, though this has not been unequivocally shown to be the case.

Combined fascial and mesh closure.

The issue of contact between the intra-abdominal viscera and the prosthesis has been further addressed by techniques that combine features of the component separation technique with the tension-free concept. The posterior fascia is closed primarily, but the anterior fascia is allowed to remain open, so that there is no tension at all. The anterior fascia is then bridged with a prosthesis.

Sublay prosthetic repair.

Sublay prosthetic repair, sometimes referred to as the retromuscular approach, is characterized by the placement of a large prosthesis in the space between the abdominal muscles and the peritoneum.

The posterior rectus sheath is opened on each edge of the hernia defect and dissected away from the undersurface of the recti or a distance of 10 to 15 cm. The posterior rectus sheaths are then approximated to each other primarily. A large mesh prosthesis (composed of e-PTFE if the approximation of the posterior rectus sheath is inadequate) is then placed in this space outside the repaired posterior sheath but beneath the recti. The mesh is secured in this position with several sutures that are placed with a suture passer through small stab incisions at the periphery of the prosthesis and tied in the subcutaneous tissue above the fascia.

Postoperative complications

1. Recurrence of the hernia after repair is estimated to occur in 3%-10% of patients.
2. Temporary urinary retention with difficulty urinating is common.
3. Wound infection occurs in 1%—3% of patients postoperatively.
4. Injury:

—to the ilioinguinal, iliohypogastric, and genital branch of the genitofemoral nerves rarely occurs and may result in paresthesias in their distribution of innervation.

—to the structures of the spermatic cord rarely occurs.

5. Seroma and hematoma.

TESTS FOR CONTROL

Chapter 1 Acute appendicitis

Tests (one answer is correct)

1. Acute appendicitis is:

- A) inflammation of the appendix;
- B) inflammation of the appendix with its perforation;
- C) nonspecific inflammation of the inner lining of the vermiform appendix that spreads to its other parts;
- D) purulent inflammation of the inner lining of the vermiform appendix that spreads to its other parts.

2. Kolesov's classification of acute appendicitis:

- A) edematous stage, purulent stage, gangrenous stage;
- B) appendicular colic, destructive appendicitis (phlegmonous, gangrenous, perforated), complicated;
- C) no complicated and complicated;
- D) phlegmonous, gangrenous, perforated.

3. Abdominal pain in patients with acute appendicitis:

- A) sudden, intensive, localized in the right part of abdomen;
- B) often begins gradually in the right lower quadrant of the abdomen;
- C) usually begins as periumbilical or epigastric pain migrating to the right lower quadrant of the abdomen;
- D) often begins as periumbilical or epigastric pain, accompanies with vomiting, nausea high temperature.

4. Describe Rovsing's sign:

- A) passive internal rotation of flexed right thigh with the patient in supine position causes pain;
- B) light percussion on McBurney's point will elicit pain;
- C) pain in the right lower quadrant is complained of when palpation pressure is exerted in the left lower quadrant;
- D) strengthening pain in the right lower square in the position of patient on the left side.

5. Describe Sitkovsky's sign:

- A) passive internal rotation of flexed right thigh with the patient in supine position causes pain;
- B) light percussion on McBurney's point elicits pain;
- C) pain in the right lower quadrant is complained of when palpation pressure is exerted in the left lower quadrant;
- D) strengthening pain in the right lower square in the position of patient on the left side.

6. Main method in diagnostic procedure is:

- A) X - ray examination;
- B) ultrasound;
- C) lab. studies;
- D) anamnestic and clinical examination.

7. Peculiarities of trends of acute appendicitis in elderly patients:

- A) often retrocaecal position of appendix;
- B) often pain accompanies with vomiting, nausea;
- C) no evident clinical picture + rapid destructive changes in appendix;
- D) often spontaneous regression of inflammation.

8. Patient 20 years old has pain in upper part of abdominal cavity with vomiting, nausea during last 2 hours. Optimal tactic is:

- A) urgent operation;
- B) antibiotics;
- C) hospitalization and observation at surgical department;
- D) observation at home by family doctor.

9. Optimal final method of differential diagnostic of acute appendicitis is:

- A) laparoscopy;
- B) ultrasound;
- C) lab. studies;
- D) anamnestic and clinical examination.

10. In preoperative preparation in patients with acute appendicitis we use:

- A) analgetics;
- B) spasmolytics;
- C) antibiotics;
- D) all answers are not correct.

11. In patients with acute appendicitis and clinical manifestation of local peritonitis surgeons use:

- A) McBurney's incision of abdominal wall;
- B) Shprengel's incision of abdominal wall;
- C) Koher's incision of abdominal wall;
- D) middle line laparotomy.

12. In patients with acute appendicitis and clinical manifestation of general peritonitis surgeons use:

- A) McBurney's incision of abdominal wall;
- B) pararectal incision of abdominal wall;
- C) Koher's incision of abdominal wall;
- D) middle line laparotomy.

13. Differential diagnostic of appendicular mass:

- A) colonic cancer;
- B) appendicular abscess;
- C) ovarium tumor;
- D) all answers are correct.

14. Final method of differential diagnostic between colonic cancer and appendicular mass is:

- A) laparoscopy;
- B) ultrasound;
- C) colonoscopy + biopsy;
- D) X - ray examination.

15. Final method of differential diagnostic between appendicular abscess and appendicular mass is:

- A) laparoscopy;
- B) ultrasound;
- C) colonoscopy + biopsy;
- D) lab. studies.

16. Clinical manifestation of appendicular abscess:

- A) temperature of body rises to 38,0-39,0°C;
- B) increasing of the size of the mass;
- C) increasing abdominal pain - suggesting spreading peritonitis;
- D) all answers are correct.

17. Ultrasound examination helps in differential diagnostic between colonic cancer and appendicular mass by:

- A) detecting of adhesions between mass and bowels;
- B) absence of adhesions between mass and bowels;
- C) increasing of mass during 2 weeks;
- D) revealing of metastasis.

18. Treatment of the intraabdominal bleeding from mesoappendix after appendectomy:

- A) laparotomy and stopping of bleeding;
- B) conservative;
- C) surgical in young patients, conservative in elderly;
- D) laparoscopy drainage.

19. Treatment of the appendicular mass:

- A) surgical;
- B) conservative;
- C) surgical in young patients, conservative in elderly;
- D) laparoscopy drainage.

20. Treatment of the pelvic abscess in man:

- A) laparotomy or laparoscopy drainage;

- B) conservative;
- C) surgical in young patients, conservative in elderly;
- D) rectal drainage.

Standards of answers

1 - C; 2 - B; 3 - C; 4 - C; 5 - D; 6 - D; 7 - C; 8 - C; 9 - A;
10 - C; 11 - A; 12 - D; 13 - D; 14 - C; 15 - B; 16 - D; 17 - D; 18 - A; 19 - B; 20 - D.

Chapter 2 Acute cholecystitis

Tests (one answer is correct)

1. Acute cholecystitis is:

- A) inflammation of gallbladder;
- B) inflammation of gallbladder with its perforation;
- C) nonspecific inflammation of gallbladder;
- D) purulent inflammation of gallbladder.

2. Risk factors for cholecystitis include:

- A) gallstones;
- B) pregnancy;
- C) cardiovascular events;
- D) all answers are correct.

3. Mark not correct answer about classification of acute cholecystitis:

- A) edematous stage, purulent stage, gangrenous stage;
- B) calculous and non-calculous;
- C) catarrhal, phlegmonous, gangrenous;
- D) not complicated and complicated.

4. Characteristic of pain in acute cholecystitis:

- A) sudden pain in the upper abdomen, has moderate intensity, constant character and not irradiate;
- B) colic pain;
- C) constant pain, may radiate to the right shoulder or scapula;
- D) "knife-like" pain.

5. Describe Murphy's sign:

- A) a delay of breathing during palpation of gallbladder on inhalation because of increasing of pain;
- B) a strengthening of pain at pressure on the area of gallbladder;
- C) a painfulness at the easy pattering on right costal arc by the edge of palm;
- D) an increasing of pain after palpation between the legs of right nodding muscle.

6. Describe Kehr's sign:

- A) a delay of breathing during palpation of gallbladder on inhalation because of increasing of pain;
- B) a strengthening of pain at pressure on the area of gallbladder;

- C) a painfulness at the easy pattering on right costal arc by the edge of palm;
- D) an increasing of pain after palpation between the legs of right nodding muscle.

7. Describe Ortner's sign:

- A) a delay of breathing during palpation of gallbladder on inhalation because of increasing of pain;
- B) a strengthening of pain at pressure on the area of gallbladder;
- C) a painfulness at the easy pattering on right costal arc by the edge of palm;
- D) an increasing of pain after palpation between the legs of right nodding muscle.

8. Describe Mussy's sign:

- A) a delay of breathing during palpation of gallbladder on inhalation because of increasing of pain;
- B) a strengthening of pain at pressure on the area of gallbladder;
- C) a painfulness at the easy pattering on right costal arc by the edge of palm;
- D) an increasing of pain after palpation between the legs of right nodding muscle.

9. Peculiarities of trends of acute appendicitis in elderly patients:

- A) often pain accompanies with vomiting, nausea;
- B) no evident clinical picture + rapid destructive changes in gallbladder;
- C) often spontaneous regression of gallbladder;
- D) all answers are correct.

10. Main method in diagnostic procedure is:

- A) X - ray examination;
- B) ultrasound;
- C) lab. studies;
- D) anamnestic and clinical examination.

11. Ultrasonographic findings of acute cholecystitis include:

- A) gallstones;
- B) free liquid in abdominal cavity;
- C) gallbladder wall thickening greater than 4 mm;
- D) all answers are correct.

12. Tactic of treatment of acute cholecystitis is:

- A) only conservative;
- B) only surgical;
- C) initial treatment is conservative + surgery for some indications;
- D) individual.

13. Indications for surgical treatment are:

- A) peritonitis;
- B) retention of abdominal pain and muscles resistance;
- C) increasing of body's temperature and leukocytosis;
- D) all answers are correct.

14. Optimal term for operation in patients with inefficacy of conservative treatment is:

- A) 2 hours;
- B) 12 hours;
- C) 24 - 48 hours;
- D) 72 hours.

15. If acute calculous cholecystitis resolves, optimal tactic is:

- A) following conservative management may be the mainstay of treatment;
- B) laparoscopic cholecystectomy has be done 2 weeks later;
- C) laparoscopic cholecystectomy has be done 4 - 6 weeks later;
- D) open cholecystectomy has be done 4 - 6 weeks later.

16. Indications for open cholecystectomy in acute cholecystitis:

- A) total terminal peritonitis;
- B) surgeon does not know how to perform a laparoscopic cholecystectomy;
- C) complications have developed or the patient has had prior surgery to the area;
- D) all answers are correct.

17. In cases of severe inflammation, shock, or if the patient has higher risk of operation the surgeon has to:

- A) perform only conservative treatment;
- B) perform immediately laparoscopic cholecystectomy;
- C) perform immediately open cholecystectomy;
- D) perform percutaneous cholecystostomy tube under ultrasound or CTscan control.

18. The most dangerous complication of laparoscopic cholecystectomy in patient with acute cholecystitis is:

- A) bile duct injury;
- B) cystic duct injury;
- C) liver injury;

D) all answers are correct.

19. Treatment of the gallbladder mass:

A) surgical;

B) conservative;

C) surgical in young patients, conservative in elderly;

D) laparoscopy drainage.

20. Treatment of the intraabdominal bleeding from cystic artery after cholecystectomy:

A) laparotomy and stopping of bleeding;

B) conservative;

C) surgical in young patients, conservative in elderly;

D) laparoscopy drainage.

Standards of answers

1 - C; 2 - D; 3 - A; 4 - C; 5 - A; 6 - B; 7 - C; 8 - D; 9 - B;

10 - B; 11 - C; 12 - C; 13 - D; 14 - C; 15 - C; 16 - D; 17 - D; 18 - A; 19 - B; 20 - A.

Chapter 3 Acute pancreatitis

Tests (one answer is correct)

1. Acute pancreatitis is:

A) inflammation of pancreas;

B) inflammation of gallbladder and pancreas;

C) autodigestion of tissues by pancreatic enzymes, and econdary infection and multiorgan system failure may be associated with autodigestion process;

D) purulent inflammation of pancreas.

2. Risk factors for cholecystitis include:

A) gallstones;

B) pregnancy;

C) fatty foods;

D) all answers are correct.

3. Mark not correct answer about classification of acute pancreatitis:

A) edematous pancreatitis and pancreonecrosis;

B) fatty and hemorrhagic pancreonecrosis;

C) catarrhal, phlegmonous, gangrenous;

D) not complicated and complicated.

4. Characteristic of pain in acute pancreatitis:

A) intensive pain in the upper abdomen, has constant character;

B) colic pain;

C) moderate pain in the upper abdomen, may radiate to the right shoulder or scapula;

D) "knife-like" pain.

5. Describe Mayo - Robson's sing:

- A) regional tension of anterior abdominal wall in epigastria region, along the projection of pancreas;
- B) palpation pain in the left costal-vertebral angle;
- C) abdominal distension in upper region;
- D) absence of pulsation of abdominal aorta in epigastria region.

6) Describe Goby's sign:

- A) regional tension of anterior abdominal wall in epigastria region, along the projection of pancreas;
- B) palpation pain in the left costal-vertebral angle;
- C) abdominal distension in upper region;
- D) absence of pulsation of abdominal aorta in epigastria region.

7) Describe Voskresensky's sign:

- A) regional tension of anterior abdominal wall in epigastria region, along the projection of pancreas;
- B) palpation pain in the left costal-vertebral angle;
- C) abdominal distension in upper region;
- D) absence of pulsation of abdominal aorta in epigastria region.

8) Describe Korte's sign:

- A) regional tension of anterior abdominal wall in epigastria region, along the projection of pancreas;
- B) palpation pain in the left costal-vertebral angle;
- C) abdominal distension in upper region;
- D) absence of pulsation of abdominal aorta in epigastria region.

9) Describe Cullen's sign:

- A) bluish discoloration around the umbilicus;
- B) reddish-brown discoloration along the flanks resulting from retroperitoneal blood dissecting along tissue planes;
- C) violet spots on the body and face;
- D) cyanosis of skin of abdominal wall.

10) Describe Mondor's sign:

- A) bluish discoloration around the umbilicus;
- B) reddish-brown discoloration along the flanks resulting from retroperitoneal blood dissecting along tissue planes;
- C) violet spots on the body and face;
- D) cyanosis of skin of abdominal wall.

11) Describe Grey-Turner's sign:

- A) bluish discoloration around the umbilicus;
- B) reddish-brown discoloration along the flanks resulting from retroperitoneal blood dissecting;
- C) violet spots on the body and face;
- D) cyanosis of skin of abdominal wall.

12) Describe Holsted's sign:

- A) bluish discoloration around the umbilicus;
- B) reddish-brown discoloration along the flanks resulting from retroperitoneal blood dissecting along tissue planes;
- C) violet spots on the body and face;
- D) cyanosis of skin of abdominal wall.

13) Main method in diagnostic procedure is:

- A) X - ray examination;
- B) ultrasound;
- C) lab. studies;
- D) anamnestic and clinical examination.

14) Specific ultrasonographic findings of acute pancreatitis include:

- A) changing in size and structure of pancreas;
- B) free liquid in abdominal cavity;
- C) gallstones;
- D) all answers are correct.

15) Tactic of treatment of acute pancreatitis is:

- A) only conservative;
- B) only surgical;
- C) initial treatment is conservative + surgery for some indications;
- D) individual.

16) Indications for surgical treatment are:

- A) peritonitis;
- B) retention of abdominal pain and muscles resistance;
- C) increasing of body's temperature and leukocytosis;
- D) formation of mass.

17) Optimal term for operation in patients with gallstones pancreatitis:

- A) 2 hours;
- B) 12 hours;
- C) 24 - 48 hours;
- D) 72 hours.

18. If acute gallstones pancreatitis resolves, optimal tactic is:

- A) following conservative management may be the mainstay of treatment;
- B) laparoscopic cholecystectomy has be done 2 weeks later;
- C) laparoscopic cholecystectomy has be done 4 - 6 weeks later;
- D) open cholecystectomy has be done 4 - 6 weeks later.

19. Indication for peritoneal lavage is:

- A) formation of mass;
- B) retroperitoneal phlegmone;
- C) increasing of body's temperature and leukocytosis;
- D) peritonitis.

20. Treatment of the pancreatic mass:

- A) surgical;
- B) conservative;
- C) surgical in young patients, conservative in elderly;
- D) laparoscopy drainage.

Standards of answers

1 - C; 2 - D; 3 - C; 4 - A; 5 - B; 6 - C; 7 - D; 8 - A; 9 - A;
10 - C; 11 - B; 12 - D; 13 - C; 14 - A; 15 - C; 16 - A; 17 - C; 18 - C; 19 - D; 20 - A.

Chapter 4 Perforated peptic ulcer

Tests (one answer is correct)

1. Risk factors for perforated ulcer include:

- A) H pylori infection;
- B) hydrochloric acid;
- C) NSAID events;
- D) all answers are correct.

2. Mark not correct answer about classification of perforated ulcer:

- A) perforation of duodenal or gastric ulcer;
- B) covered and atypical perforation;
- C) perforation with peritonitis and perforation without peritonitis;
- D) perforation has 3 stages.

3. Describe Ratner's sign:

- A) an irradiation of pain to the right shoulder or scapula;
- B) a strengthening of pain at pressure on the area of stomach;
- C) a painfulness at the easy pattering on right costal arc by the edge of palm;

D) a persisting moderate tenderness of abdominal wall in right epigastria region.

4. Describe Elicer's sign:

A) an irradiation of pain to the right shoulder or scapula;

B) a strengthening of pain at pressure on the area of gallbladder.

C) a painfulness at the easy patting on right costal arc by the edge of palm.

D) persisting moderate tenderness of abdominal wall in right epigastria region.

5. Ratner's sign is a sign of:

A) stomach perforation;

B) covered perforation;

C) stage of illusions;

D) atypical perforation.

6. Initial method in diagnostic procedure is:

A) X - ray examination;

B) ultrasound;

C) lab. studies;

D) laparoscopy.

7. Tactic of treatment of perforated ulcer is:

A) conservative;

B) surgical;

C) initial treatment is conservative + surgery for some indications;

D) surgical in young patients, conservative in elderly patients.

8. Optimal term for operation in patients with perforated ulcer is:

A) 2 hours;

B) 12 hours;

C) 24 - 48 hours;

D) 72 hours.

9. Surgical procedures for perforated ulcer are:

A) simple closure;

B) ulcer exision;

C) partial gastrectomy;

D) all answers are correct.

10. Contraindication for laparoscopic surgery for perforated ulcer is:

A) total terminal peritonitis;

B) surgeon does not know how to perform a laparoscopic repair;

C) fatal cardiovascular events;

D) all answers are correct.

Standards of answers

1 - D; 2 - C; 3 - D; 4 - A; 5 - B; 6 - A; 7 - B; 8 - A; 9 - D;
10 - D.

Chapter 5 Peptic ulcer acute hemorrhage

Tests (one answer is correct)1. Acute peptic ulcer hemorrhage is:

- A) destruction of vessel in ulcer with flow of blood;
- B) destruction of vessel in ulcer with flow of blood with hematomesis and melena;
- C) destruction of vessel in ulcer with flow of blood with hematomesis, melena and multiorgan system disturbances;
- D) all answers are correct.

2. Risk factors of peptic ulcer hemorrhage include:

- A) H pylori infection;
- B) hydrochloric acid;
- C) NSAID events;
- D) all answers are correct.

3. Mark not correct answer about classification of peptic ulcer hemorrhage:

- A) bleeding duodenal or gastric ulcer;
- B) there are 3 stages of loss of blood;
- C) Forrest classification correspondences with loss of blood;
- D) Forrest classification correspondences with kind of hemostasis.

4. Characteristic of pain peptic ulcer hemorrhage:

- A) intensive pain in the upper abdomen, has constant character;
- B) pain has stopped after beginning of hemorrhage;
- C) moderate pain in the upper abdomen, may radiate to the right shoulder or scapula;
- D) colic pain.

5. Describe Bergmann's sign:

- A) pain has stopped after beginning of hemorrhage;
- B) palpation pain in the left costal-vertebral angle;
- C) abdominal distension in upper region;
- D) absence of pulsation of abdominal aorta in epigastria region as a result of stomach dilatation.

6. Diagnostic procedure in peptic ulcer hemorrhage includes:

- A) X - ray examination;
- B) ultrasound;
- C) digital examination of rectum;
- D) CT scan.

7. Diagnosis program includes:

- A) anamnesis and physical examination;
- B) digital examination of rectum;
- C) EFGDS;
- D) all answers are correct.

8. Tactic of treatment of peptic ulcer hemorrhage is:

- A) only conservative;
- B) only surgical;
- C) EFGDS hemostasis + conservative treatment + surgery for some indications;
- D) initial treatment is conservative + surgery for some indications.

9. Absolute indications for surgical treatment are:

- A) prolonged bleeding;
- B) recurrent bleeding;
- C) perforated bleeding ulcer;
- D) all answers are correct.

10. Optimal term for operation in patients with absolute indications for surgical treatment:

- A) 2 hours;
- B) 12 hours;
- C) 24 - 48 hours;
- D) 72 hours.

11. Relative indication for surgical treatment is:

- A) high risk of recurrent bleeding;
- B) massive bleeding;
- C) prolonged bleeding in older patients;
- D) suspicion about stomach cancer.

12. Optimal term for operation in patients with relative indications for surgical treatment:

- A) 2 hours;
- B) 12 hours;
- C) 24 - 48 hours;

D) 72 hours

13. Indication for angiographic embolization is:

A) bleeding ulcer of stomach;

B) high risk for surgical intervention;

C) recurrent bleeding;

D) bleeding recurrent ulcer after open surgery.

14. Contraindication for emergency EFGDS is:

A) Zenker diverticulum;

B) upper abdominal open surgery;

C) severe cardiac and lung decompensation;

D) all answers are correct.

15. Tactic of treatment of perforated bleeding ulcer is:

A) conservative;

B) surgical;

C) initial treatment is conservative + surgery for some indications;

D) surgical in young patients, conservative in elderly patients.

16. Optimal term for operation in patients with perforated bleeding ulcer is:

A) 2 hours;

B) 12 hours;

C) 24 - 48 hours;

D) 72 hours.

17. Surgical procedure for perforated bleeding ulcer is:

A) simple closure;

B) laparoscopy repair;

C) ulcer excision;

D) all answers are correct.

18. Surgical procedure for bleeding duodenal ulcer is:

A) simple closure;

B) ulcer excision + pyloroduodenoplasty;

C) partial gastrectomy;

D) all answers are correct.

19. Surgical procedure for bleeding gastric ulcer is:

A) simple closure;

B) ulcer excision + truncal vagotomy;

C) partial gastrectomy;

D) all answers are correct.

20. Surgical procedure for bleeding gastric ulcer in elderly patients is:

A) simple closure;

B) ulcer excision;

C) partial gastrectomy;

D) all answers are correct.

Standards of answers

1 - C; 2 - D; 3 - C; 4 - B; 5 - A; 6 - C; 7 - D; 8 - C; 9 - D;

10 - A; 11 - A; 12 - C; 13 - B; 14 - C; 15 - B; 16 - A; 17 - C; 18 - B; 19 - C; 20 - B.

Chapter 6 Bowel obstruction

Tests (one answer is correct)1. Small bowel blood supply is (arteries):

- A) a. mesenteric superior;
- B) a. mesenteric inferior;
- C) truncus celiacus;
- D) a. gastric dextra.

2. Large bowel blood supply is (arteries):

- A) a. mesenteric superior;
- B) a. mesenteric inferior;
- C) Rioliary ark;
- D) all answers are correct.

3. Venous bowel outflow is:

- A) v. cava superior;
- B) v. cava inferior;
- C) portal vein;
- D) all answers are correct.

4. Mark not correct answer about clinical classification of bowel obstruction:

- A) acute;
- B) subacute;
- C) chronic;
- D) mechanical.

5. Classification of ileus:

- A) after abdominal injury;
- B) paralytic or spastic;
- C) after central nerve system injury;
- D) all answers are correct.

6. Classification of large bowel obstruction:

- A) obstructive;
- B) strangulated;
- C) acute and chronic;
- D) all answers are correct.

7. Main sing of bowel obstruction:

- A) constant pain;
- B) cramp-like pain;
- C) hyperthermia;
- D) weakness.

8. Main sing of small bowel obstruction:

- A) hyperthermia;
- B) vomiting;
- C) absence of gas and stool;
- D) weakness.

9. Main sing of large bowel obstruction:

- A) hyperthermia;
- B) vomiting;
- C) absence of gas and stool;
- D) weakness.

10. Intensive pain is observed in patients with:

- A) obstructive bowel obstruction;
- B) strangulated bowel obstruction;
- C) acute bowel obstruction;
- D) paralytic bowel obstruction.

11. Paralytic bowel obstruction usually occurs after:

- A) abdominal injury;
- B) laparoscopy;
- C) laparotomy;
- D) all answers are correct.

12. Obstructive bowel obstruction may be caused by:

- A) tumors;

- B) gallstones;
- C) coproliths;
- D) all answers are correct.

13. In elderly patients the most frequent cause of obstructive bowel obstruction is:

- A) tumors;
- B) gallstones;
- C) coproliths;
- D) all answers are correct.

14. The most frequent localisation of tumors which are complicated with obstructive bowel obstruction

is:

- A) cecum;
- B) ascendant colon;
- C) transversal colon;
- D) descendant and sigmoid colon.

15. In diagnostic program for bowel obstruction we use:

- A) plain radiography;
- B) enteroclysis;
- C) ultrasonography;
- D) all answers are correct.

16. Tactic of treatment of bowel obstruction is:

- A) conservative;
- B) surgical;
- C) initial treatment is conservative + surgery for some indications;
- D) surgical in young patients, conservative in elderly patients.

17. The main sign of nonviability of bowel:

- A) changing of color;
- B) absents of pulsation of mesenteric arteries;
- C) decreasing of motor activity;
- D) all answers are correct.

18. The limits of resection of small bowel are:

- A) nonviability part + 40 cm before + 20 cm late;
- B) nonviability part + 20 cm before + 10 cm late;
- C) only nonviability part;
- D) surgeon has to detect individually.

19. Optimal surgical procedure in patients with tumor of ascendant colon and bowel obstruction:

- A) tumor + 40 cm before + 20 cm late;
- B) right hemicolectomy + enterostomy;
- C) right hemicolectomy + ileotransversostomy;
- D) surgeon has to detect individually.

20. Optimal surgical procedure in patients with tumor of descendant colon and bowel obstruction:

- A) tumor + 40 cm before + 20 cm late;
- B) left hemicolectomy + colostomy;
- C) left hemicolectomy + transversosigmoidostomy;
- D) surgeon has to detect individually.

Standards of answers

- 1 - A; 2 - D; 3 - C; 4 - D; 5 - B; 6 - D; 7 - B; 8 - B; 9 - C;
10 - B; 11 - C; 12 - D; 13 - A; 14 - D; 15 - D; 16 - C; 17 - B; 18 - A; 19 - C; 20 - B.

Chapter 7 Acute peritonitis

Tests (one answer is correct)

1. Mark not correct answer. The organs are divided into:

- A) intraperitoneal;
- B) mesoperitoneal;
- C) extraperitoneal;
- D) mixed position.

2. Normally, the amount of peritoneal fluid present is less than:

- A) 10 ml;
- B) 50 ml;
- C) 100 ml;
- D) 150 ml.

3. Classification of peritonitis according to origin includes:

- A) perforated;
- B) serose;
- C) primary;
- D) reactive phase.

4. Classification of peritonitis according to cause includes:

- A) perforated;
- B) serose;
- C) primary;
- D) reactive phase.

5. Classification of peritonitis according to character of exudate includes:

- A) perforated;
- B) serose;
- C) primary;
- D) reactive phase.

6. Classification of phases of peritonitis includes:

- A) perforated;
- B) serose;
- C) primary;
- D) reactive phase.

7. Classification of phases of peritonitis doesn't include:

- A) initial;
- B) reactive;
- C) toxic;
- D) terminal.

8. Pathophysiology of the reactive phase includes:

- A) respiratory distress syndrome;
- B) appearance of exudate into abdominal cavity;
- C) adynamic ileus when distended bowel wall loses barrier function;
- D) all answers are correct.

9. Pathophysiology of the toxic phase includes:

- A) respiratory distress syndrome;
- B) appearance of exudate into abdominal cavity;
- C) adynamic ileus when distended bowel wall loses barrier function;
- D) all answers are correct.

10. Pathophysiology of the terminal phase includes:

- A) respiratory distress syndrome;
- B) appearance of exudate into abdominal cavity;
- C) adynamic ileus when distended bowel wall loses barrier function;
- D) all answers are correct.

11. General tactic of treatment of acute peritonitis is:

- A) conservative;
- B) surgical;
- C) initial treatment is conservative + surgery for some indications;

D) surgical in young patients, conservative in elderly patients.

12. Tactic of treatment of tuberculous peritonitis is:

A) specific therapy;

B) surgical;

C) initial treatment is conservative + surgery for some indications;

D) surgical in young patients, conservative in elderly patients.

13. Preoperative preparation in acute peritonitis:

A) it is prescribed individually;

B) it isn't indicated;

C) it is necessary for all patients with acute peritonitis;

D) it is necessary in the terminal phase.

14. Antibacterial therapy in acute peritonitis:

A) it isn't indicated;

B) it is starting before the operation;

C) it is starting at the operation;

D) it is starting after the operation.

15. Contraindication for ultrasound- and CT-guided percutaneous drainage of abdominal abscess is:

A) subphrenic abscess;

B) multiple or multiloculated abscesses;

C) subhepatic abscess;

D) parapancreatic abscess.

16. Laparoscopic sanitation of the abdominal cavity isn't effective in:

A) perforated peritonitis;

B) pancreatogenic peritonitis;

C) elderly patients;

D) terminal phase with multiloculated abscesses.

17. In patients with general peritonitis surgeons use:

A) McBurney's incision of abdominal wall;

B) pararectal incision of abdominal wall;

C) lockal incisions of abdominal wall;

D) middle line laparotomy.

18. The main reasons of surgical treatment in acute peritonitis are:

A) adequate sanitation of abdominal cavity;

B) source control;

C) gastrointestinal decompression;

D) all answers are correct.

19. Required quantity of solutions for adequate sanitation of abdominal cavity in patients with total peritonitis is:

A) 5 liters;

B) 10 liters;

C) 15 liters;

D) 20 liters.

20. The inspection method after operation is:

A) open-abdomen technique;

B) scheduled relaparotomy;

C) scheduled relaparoscopy;

D) all answers are correct.

Standards of answers

1 - D; 2 - B; 3 - C; 4 - A; 5 - B; 6 - D; 7 - A; 8 - B; 9 - C;

10 - A; 11 - B; 12 - A; 13 - C; 14 - B; 15 - B; 16 - D; 17 - D; 18 - D; 19 - C; 20 - D.

Chapter 8 Hernias of abdominal wall

Tests (one answer is correct)

1. The contributes factor of hernias is:

- A) hard physical activity;
- B) weight loss;
- C) chronic cough;
- D) chronic constipation.

2. The causes factor of hernias is:

- A) congenital weakness of the abdominal wall;
- B) weight loss;
- C) chronic cough;
- D) pregnancy.

3. The sliding hernia occurs when:

- A) patient has congenital weakness of the abdominal wall;
- B) the hernia's sac is absent;
- C) the hernia's sac is formed by the strangulated bowel;
- D) the hernia's sac is partially formed by the wall of an organ without peritoneal covering.

4. Classification of hernias of the abdominal wall according to localization doesn't include:

- A) diaphragmatic hernia;
- B) midline hernia;
- C) femoral hernia;
- D) umbilical hernia.

5. Classification of hernias complications doesn't include:

- A) incarceration;
- B) strangulation;
- C) sliding hernia;
- D) inflammation.

6. Main method in diagnostic procedure is:

- A) X - ray examination;
- B) ultrasound;
- C) lab. studies;
- D) anamnestic and clinical examination.

7. Clinical manifestations of strangulated hernia:

- A) acute pain;
- B) incarceration;
- C) vomiting;
- D) all answers are correct.

8. Differential sing between incarcerated and strangulated hernias is:

- A) "cough push" sing;
- B) Blumberg sing;
- C) cramp-like abdominal pain;
- D) all answers are correct.

9. Final method of differential diagnostic between incarcerated and strangulated hernias is:

- A) laparocentesis;
- B) ultrasound;
- C) herrniotomy;
- D) X - ray examination.

10. Treatment of the patients with strangulated hernias is:

- A) conservative;
- B) surgical;

- C) surgical in young patients, conservative in elderly;
- D) symptomatic treatment.

11. Optimal term for operation in patients with strangulated hernia is:

- A) 2 hours;
- B) 12 hours;
- C) 24 - 48 hours;
- D) 72 hours.

12. The limits of resection of small bowel in patients with strangulated hernia are:

- A) nonviability part + 40 cm before + 20 cm late;
- B) nonviability part + 20 cm before + 10 cm late;
- C) only nonviability part;
- D) surgeon has to detect individually.

13. Optimal surgical procedure in patients with strangulated hernia and nonviability of sigmoid colon is:

- A) nonviability part + 40 cm before + 20 cm late;
- B) resection of sigmoid colon_+ colostomy;
- C) resection of sigmoid colon_+ primary anastomosis;
- D) surgeon has to detect individually.

14. Differential sing of the sliding inguinal hernia is:

- A) cramp-like abdominal pain;
- B) incarceration;
- C) dysuria;
- D) all answers are correct.

15. Optimal surgical procedure in inguinal hernia:

- A) Bassini repair;
- B) Lichtenstein repair;
- C) Postempsky repair;
- D) MacVay repair.

15. Optimal surgical procedure in femoral hernia:

- A) Bassini repair;
- B) Lichtenstein repair;
- C) Postempsky repair;
- D) MacVay repair.

16. Optimal surgical procedure in umbilical hernia:

- A) Bassini repair;
- B) Lichtenstein repair;
- C) Postempsky repair;
- D) Mayo repair.

17. Optimal surgical procedure in postoperative hernia:

- A) simple nonprosthetic repair;
- B) "onlay" repair;
- C) "sublay" repair;
- D) all answers are correct.

18. More frequent postoperative complication in patients with "gigantic" hernias is:

- A) pulmonary embolism;
- B) abdominal compartment syndrome;
- C) wound infection;
- D) systemic fat embolism.

19. More frequent postoperative complication after simple nonprosthetic repair is:

- A) seroma;
- B) wound infection;
- C) recurrence of the hernia;
- D) systemic fat embolism.

20. More frequent postoperative complication after prosthetic "onlay" repair is:

- A) seroma;
- B) wound infection;
- C) recurrence of the hernia;
- D) lymphorrhea.

Standards of answers

1 - B; 2 - C; 3 - D; 4 - A; 5 - C; 6 - D; 7 - D; 8 - A; 9 - C;
10 - B; 11 - A; 12 - A; 13 - B; 14 - C; 15 - A; 16 - D; 17 - C; 18 - B; 19 - C; 20 - D.

PROBLEMS

Young man, 22 years old, has moderate pain in suprapubic region, dysuria. He is suffered from abdominal pain 2 days. Pain started as diffuse lower part abdominal pain end after 12 hours localized in suprapubic region. Temperature of body is 37,8°C. Signs of peritonitis are negative.

1. What is provisional diagnosis:
 - A) acute cystitis;
 - B) acute prostatitis;
 - C) acute appendicitis;
 - D) renal colic.
2. What lab. study is the most informative:
 - A) white blood cell count;
 - B) urinalysis;
 - C) CRP;
 - D) all studies are not specific.
3. What investigation is the most informative:
 - A) excretory urography;
 - B) CT scan of abdominal cavity;
 - C) abdominal plain film;
 - D) cystoscopy.
4. Tactic of treatment:
 - A) emergency surgery;
 - B) analgetic + antibiotics;
 - C) analgetic + uroseptics;
 - D) surgery if conservative treatment is not successful.
5. The cause of misdiagnosis is:
 - A) patient's age ;
 - B) patient's sex;
 - C) late hospitalization;
 - D) unusual pelvic position of appendix.

Standards of answers

1 - C; 2 - D; 3 - B; 4 - A; 5 - D.

Woman, 62 years old, has pain in right subcostal region, vomiting with bile. Pain started as a colic pain after fatty food intake, after 2 hours became constant. Temperature of body is 37,4°C. During palpation painfulness and muscle resistance are observed in right subcostal region. Blumberg sign is negative.

1. What is provisional diagnosis:

- A) acute cholecystitis;
- B) acute gastritis;
- C) acute appendicitis;
- D) renal colic.

2. What lab. study is the most informative:

- A) white blood cell count;
- B) urinalysis;
- C) CRP;
- D) all studies are not specific.

3. What investigation is the most informative:

- A) excretory urography;
- B) ultrasound scan of abdominal cavity;
- C) abdominal plain film;
- D) chest film.

4. Tactic of treatment:

- A) emergency surgery;
- B) conservative treatment;
- C) gallstones - emergency surgery;
- D) surgery if conservative treatment is not successful.

5. If conservative treatment of acute calculous cholecystitis is successful:

- A) surgery is indicated after next pain attack;
- B) surgery is not indicated;
- C) surgery is performed after 1 month;
- D) surgery is performed after 6 months.

Standards of answers

1 - A; 2 - D; 3 - B; 4 - D; 5 - C.

Woman, 59 years old, has intensive upper abdominal pain, vomiting. Pain started after fatty meat intake 12 hours ago. Scleras are icteric. During palpation painfulness and muscle resistance are observed in upper abdomen. Blumberg sign is negative. Last 2 years patient noted periodical colic pain in right subcostal region.

1. What is provisional diagnosis:

- A) acute cholecystitis;
- B) acute hepatitis;
- C) acute pancreatitis;
- D) food toxicoinfection.

2. What lab. study is the most informative:

- A) white blood cell count;
- B) level of serum amylase;
- C) CRP;
- D) all studies are not specific.

3. What investigation is the most indicated:

- A) endoscopic retrograde cholangiopancreatography;
- B) ultrasound scan of abdominal cavity;
- C) abdominal plain film;
- D) CT scan of abdominal cavity.

4. The most probable etiological factor:
 - A) peptic ulcer;
 - B) hepatitis;
 - C) gallstones;
 - D) toxic factor.
5. Tactic of treatment:
 - A) emergency surgery;
 - B) conservative treatment;
 - C) surgery if conservative treatment is not successful after 12 - 24 hours;
 - D) surgery if conservative treatment is not successful after 24 - 48 hours.

Standards of answers

1 - C; 2 - B; 3 - B; 4 - C; 5 - D.

Young man, 28 years old, has intensive diffuse abdominal pain. Pain started 2 hours ago after physical training. Temperature of body is 36,9°C. Last year patient noted periodical pain in stomach. Tenderness of abdominal wall, Blumberg sign are present.

1. What is provisional diagnosis:
 - A) acute cholecystitis;
 - B) acute pancreatitis;
 - C) perforated ulcer;
 - D) acute gastritis.
2. What lab. study is the most informative for differential diagnostics:
 - A) white blood cell count;
 - B) CRP;
 - C) level of serum amylase;
 - D) all studies are not informative.
3. What investigation is the most informative:
 - A) gastroscopy;
 - B) ultrasound scan of abdominal cavity;
 - C) abdominal plain film;
 - D) laparoscopy.
4. Tactic of treatment:
 - A) emergency surgery;
 - B) conservative treatment (Taylor method);
 - C) surgery if conservative treatment is not successful after 12 hours;
 - D) surgery if conservative treatment is not successful after 24 hours.
5. The best method for perforated duodenal ulcer is:
 - A) ulcer excision;
 - B) ulcer excision + vagotomy;
 - C) ulcer excision + adequate antiulcer treatment;
 - D) partial gastrectomy.

Standards of answers

1 - C; 2 - C; 3 - D; 4 - A; 5 - C.

Young man, 34 years old, has coffee ground vomiting and melena during 20 hours. Pulse rate is 100 per min., decreasing of arterial blood pressure is 90/60 mm Hg.

1. What is provisional loss of blood:
 - A) "microbleeding";
 - B) I - II stage;
 - C) III stage;
 - D) profuse bleeding.
2. What investigation is the most informative:
 - A) gastroscopy;
 - B) ultrasound scan of abdominal cavity;
 - C) abdominal plain film;
 - D) laparoscopy.
3. Tactic of treatment:
 - A) emergency surgery;
 - B) medicamentous hemostasis;
 - C) endoscopic hemostasis;
 - D) endoscopic hemostasis + medicamentous hemostasis.
4. The best method for hemostasis control:
 - A) puls rate;
 - B) blood pressure;
 - C) clinical observation;
 - D) endoscopic observation.
5. The best procedure for bleeding duodenal ulcer is:
 - A) ulcer excision;
 - B) ulcer excision + vagotomy;
 - C) ulcer excision + adequate antiulcer treatment;
 - D) partial gastrectomy.

Standards of answers

1 - B; 2 - A; 3 - D; 4 - D; 5 - C.

Woman, 70 years old, has moderate crampy abdominal pain, constipation, abdominal distension during 4 days. 2 hours became constant. Temperature of body is 37,4°C. During palpation diffuse painfulness without muscle resistance is observed. Blumberg sign is negative. Digital rectal examination - empty rectum.

1. What is provisional diagnosis:
 - A) acute colitis;
 - B) small bowel obstruction;
 - C) large bowel obstruction;
 - D) coprostasis.
2. What lab. study is the most informative for differential diagnostics:
 - A) white blood cell count;
 - B) CRP;
 - C) hematocrit level;
 - D) all studies are not informative.
3. What investigation is the most informative for differential diagnostics:
 - A) CT scan of abdominal cavity;
 - B) ultrasound scan of abdominal cavity;
 - C) abdominal plain film;
 - D) laparoscopy.
4. Tactic of treatment:

- A) emergency surgery;
 - B) conservative treatment;
 - C) surgery if conservative treatment is not successful;
 - D) colonoscopic procedures.
5. The best method for control of conservative treatment efficiency:
- A) puls rate;
 - B) X - ray observation;
 - C) clinical observation;
 - D) clinical + X - ray observation.

Standards of answers

1 - C; 2 - D; 3 - C; 4 - C; 5 - D.

Young man, 25 years old, has diffuse abdominal pain, vomiting. He is suffered from abdominal pain 4 days. Pain started as diffuse lower part abdominal pain, after some hours localized in right lower quadrant, became general again on the 3 day. Temperature of body is 38,5°C. Tenderness of abdominal wall, Blumberg sine are present.

1. What is the most probable cause of peritonitis:
 - A) acute cholecystitis;
 - B) acute pancreatitis;
 - C) acute appendicitis;
 - D) perforated ulcer.
2. What lab. study is the most impotent for patient:
 - A) CBC with differential, serum electrolytes with renal function;
 - B) urinalysis;
 - C) CRP;
 - D) liver tests.
3. What investigation is the most informative:
 - A) ultrasound scan of abdominal cavity;
 - B) CT scan of abdominal cavity;
 - C) abdominal plain film;
 - D) which is necessary for preoperative preparation.
4. Tactic of treatment:
 - A) emergency surgery;
 - B) conservative treatment (Taylor method);
 - C) surgery if conservative treatment is not successful;
 - D) emergency surgery after preoperative preparation.
5. Optimal surgical incision for patient:
 - A) McBurney incision;
 - B) middle line laparotomy;
 - C) right side pararectal laparotomy;
 - D) right side transrectal laparotomy.

Standards of answers

1 - C; 2 - A; 3 - D; 4 - D; 5 - B.

Bibliography

Obligatory literature

1. 1. Acute surgical management / editors, Nian Chih Hwang, Lucien Ooi London. - Singapore : World Scientific Publishing Co. Pte. Ltd., 2004. - 717 p.
2. 2. General surgery: brief manual and guidance / D.E. Klokol.- Lugansk: Шико, 2008. - 169 p.
3. 3. Hospital surgery / L. Kovalchuk, V. Sayenko, G. Knyshov, M. Nychytailo. - Ternopil: Ukrmedknyha, 2004. - 472 p.
4. 4. Methods of examination of a surgical patient /M.A. Lyapis.- Ternopil: Ukrmedknyha, 2004.- 156 p.
5. 5. Surgical diseases: Навчальний посібник. - Simferopol, 2005. - 368 p.
6. 6. The Year Book of surgery. Chicago, 1989. -443 p.

Faculty literature

1. 1. Abraham E, Laterre PF, Garg R: Drotrecogin alfa (activated) for adults with severe sepsis and a low risk of death. N Engl J Med 2005 Sep 29; 353(13): 1332-41.
2. 2. Andersen BR, Kallehave FL, Andersen HK: Antibiotics versus placebo for prevention of postoperative infection after appendicectomy. Cochrane Database Syst Rev 2003; CD001439.
3. 3. Angus DC, Laterre PF, Helterbrand J: The effect of drotrecogin alfa (activated) on long-term survival after severe sepsis. Crit Care Med 2004 Nov; 32(11): 2199-206.
4. 4. Barcia J, Reissenweber N: Neutrophil count in the normal appendix and early appendicitis: diagnostic index of real acute inflammation. Ann Diagn Pathol 2002 Dec; 6(6): 352-6.
5. 5. Baradaran R, Ramdhaney S, Chapalamadugu R: Early intensive resuscitation of patients with upper gastrointestinal bleeding decreases mortality. Am J Gastroenterol 2004 Apr; 99(4): 619-22.
6. 6. Bhattacharya D, Ammori BJ: Contemporary minimally invasive approaches to the management of acute cholecystitis: a review and appraisal. Surg Laparosc Endosc Percutan Tech 2005 Feb;

- 15(1): 1-8.
7. 7. Bini EJ, Cohen J: Endoscopic treatment compared with medical therapy for the prevention of recurrent ulcer hemorrhage in patients with adherent clots. *Gastrointest Endosc* 2003 Nov; 58(5): 707-14.
 8. 8. Bolandparvaz S, Vasei M, Owji AA, et al: Urinary 5-hydroxy indole acetic acid as a test for early diagnosis of acute appendicitis. *Clin Biochem* 2004 Nov; 37(11): 985-9.
 9. 9. Brivet FG, Smadja C, Hilbert U: Usefulness of abdominal CT scan in severe peritoneal sepsis linked to primary peritonitis. *Scand J Infect Dis* 2005; 37(1): 76-8.
 10. 10. Dahabreh Z, Dimitriou R, Chalidis B: Coagulopathy and the role of recombinant human activated protein C in sepsis and following polytrauma. *Expert Opin Drug Saf* 2006 Jan; 5(1): 67-82.
 11. 11. Dellinger EP: Surgical infections. In: *Greenfield's Surgery: Scientific Principles And Practice*. 4th ed. 2006: 163-177.
 12. 12. Eatock FC, Chong P, Menezes N, et al: A randomized study of early nasogastric versus nasojejunal feeding in severe acute pancreatitis. *Am J Gastroenterol* 2005 Feb; 100(2): 432-439.
 13. 13. Ko CW, Beresford SA, Schulte SJ: Incidence, natural history, and risk factors for biliary sludge and stones during pregnancy. *Hepatology* 2005 Feb; 41(2): 359-65.
 14. 14. Nathens AB, Curtis JR, Beale RJ, et al: Executive summary: management of the critically ill patient with severe acute pancreatitis. *Proc Am Thorac Soc* 2004; 1(4): 289-90.
 15. 15. Parrillo JE: Severe sepsis and therapy with activated protein C. *N Engl J Med* 2005 Sep 29; 353(13): 1398-400.
 16. 16. Sgouros SN, Vlachogiannakos J, Vassiliadis K, et al: Effect of polyethylene glycol electrolyte balanced solution on patients with acute colonic pseudo obstruction after resolution of colonic dilation: a prospective, randomised, placebo controlled trial. *Gut* 2006 May; 55(5): 638-42.
 17. 17. Shaffer EA: Epidemiology and risk factors for gallstone disease: has the paradigm changed in the 21st century? *Curr Gastroenterol Rep* 2005 May; 7(2): 132-40.
 18. 18. Stefanidis D, Brown K, Nazario H, et al: Safety and efficacy of metallic stents in the management of colorectal obstruction. *JLS* 2005 Oct-Dec; 9(4): 454-9.
 19. 19. Zeerleder S, Hack CE, Willemin WA: Disseminated intravascular coagulation in sepsis. *Chest* 2005 Oct; 128(4): 2864-75.
 - 20.


Additions

Addition A. Algorithm of diagnostic of acute appendicitis

(obligatory)

Pain in right low quadrant of abdomen

↑
Kocher's sign, local pain, mussel's resistance



Yes No
 ←—————

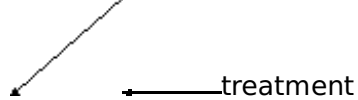
USound
 ↓

Pathology of gallbladder,
 pancreas, kidneys,
 gynecology



No Yes
 ↙ →

Laparoscopy Special



Acute appendicitis, Surgical pathology Additional
 → surgery is absent examination
 ←

Addition B. Algorithm of diagnostic and treatment of appendicular mass and abscess

(obligatory)

Mass in right low quadrant of abdomen

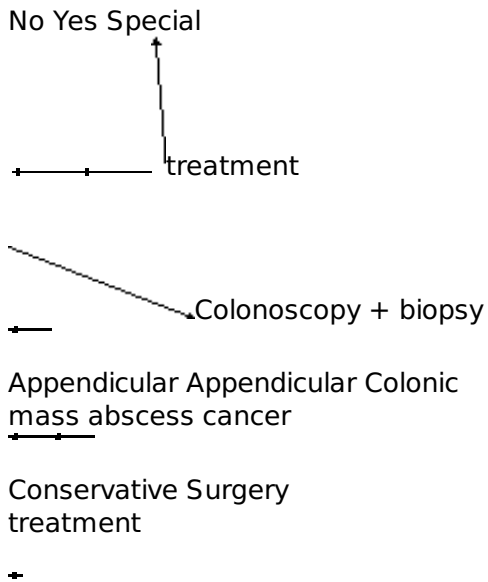
Ultrasound

← ↓ ↘
 Mass of caecum Abscess Pathology of kidneys,



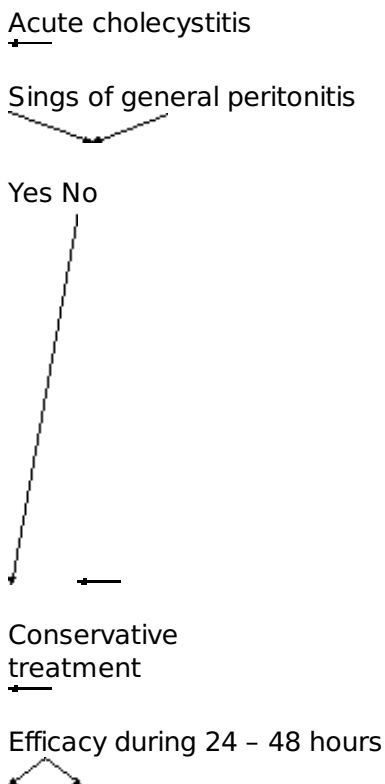
→ gynecology
 ← "Mts" in liver,
 paraaortical
 lymph nodes

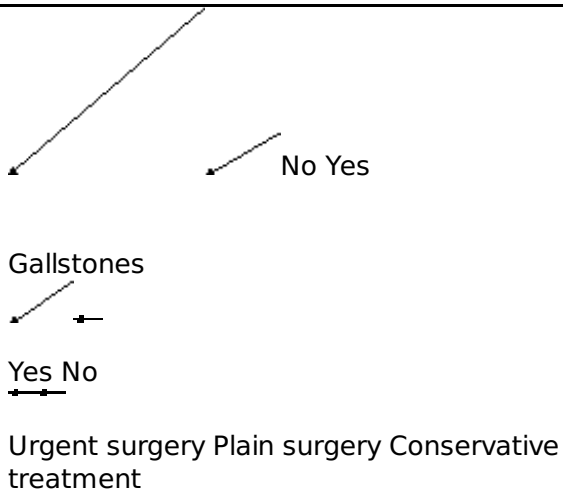




Addition C. Algorithm of treatment of acute cholecystitis

(obligatory)





Addition D. Algorithm of diagnosis and treatment

of acute pancreatitis

(obligatory)

Acute upper abdominal pain

Serum amylase and lipase levels


+

Ultrasound


Enzyme's levels are normal Increasing of amylase
 US changing of pancreas and lipase levels.
 are absent US changing of pancreas

are present

Sings of peritonitis



Yes No



Surgery Conservative treatment of acute pancreatitis

Addition E. Algorithm of diagnosis and treatment


of perforated ulcer

(obligatory)


Acute abdominal pain "due to stabbing with a dagger"



Abdominal X - Ray



Pneumoperitoneum



Yes No



FGDS + Ultrasound Laparoscopy



X-Ray

Free liquid



Laparocentesis



Perforated ulcer



Open Laparoscopic procedure repair

Addition F. Algorithm of diagnosis and treatment

of bleeding ulcer

(obligatory)

Weakness, haematomesis, melena



Emergency EFGDG



Forrest I Forrest II Forrest III



EFGDS haemostasis + conservative therapy



Evaluation of effect using clinical and EFGDS control



Forrest I Forrest II Forrest III



Absolute Relative Prolongation indication of conservative for surgery for surgery therapy



Removal of all ulcer substrates is necessary

(ulcer excision, partial gastrectomy)

Addition G. Algorithm of diagnosis and treatment

of bowel obstruction

(obligatory)

Cramp-like abdominal pain, vomiting, constipation

Signs of peritonitis, strangulation

Yes No

Preoperative Abdominal X - ray + preparation barium meal intake

Conservative treatment

Clinical evaluation + X - ray control of efficiency after 4 - 6 hours

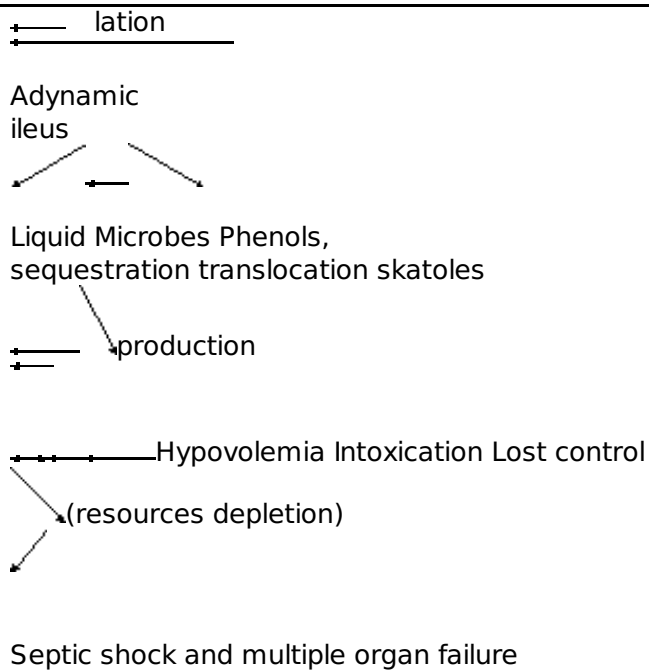
No Yes

Surgical procedure

Addition H. Pathogenesis of acute peritonitis
(obligatory)

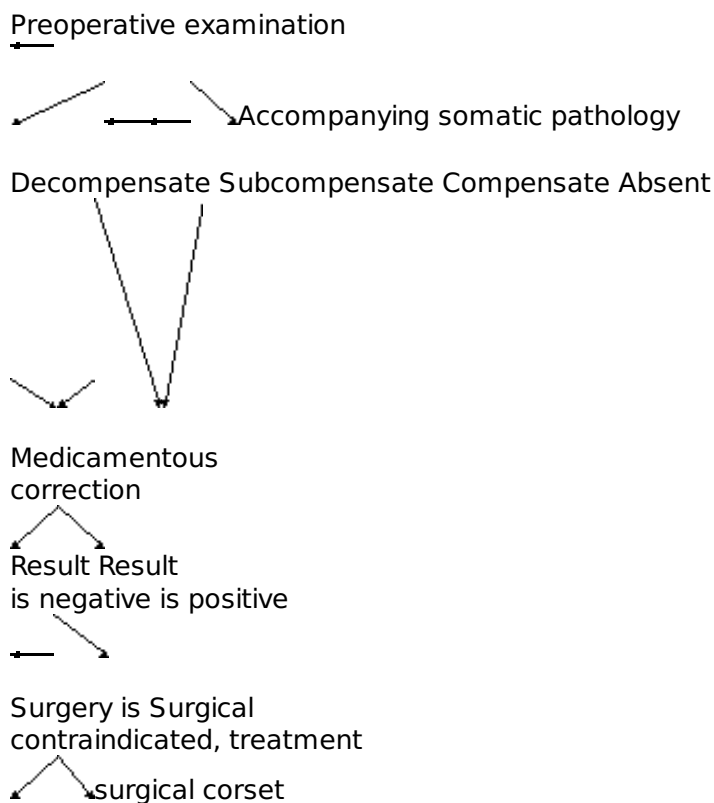
Aggressive, infected content has gotten into abdominal cavity

Inflammatory response Activation of immune system, biological into abdominal cavity active substances, hypothalamo - (edema, hyperemia, pituitary-adrenal axis exudation)
Peritoneal Hypoxia of Multiplication Released Disturbances of exudate bowel wall of microbes cathepsins microcircu-



Addition K. Algorithm of treatment of hernias

(obligatory)



Repair by local Alloplasty
tissues

Addition L. Algorithm of treatment of the


strangulated hernia

(obligatory)

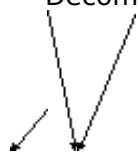← Acute pain, incarceration, vomiting

← Preoperative examination

Accompanying somatic pathology




Decompensate Compensate Absent



← Short-term preoperative preparation

Surgical Surgical
treatment treatment



Palliative Repair by local Alloplasty

correction tissues
(removal of
strangulation
without plasty)

Subject index

Acute appendicitis	5, 28
Acute cholecystitis	15,23
Acute pancreatitis	15, 30, 35
Acute peritonitis	92
Appendectomy	18,19
Atypical perforation	53, 55
Cholecystectomy	31, 33
Cholecystostomy	31
Choledocholithiasis	24,26
Classifications:	
acute appendicitis	6
acute cholecystitis	23
acute pancreatitis	40, 41
acute peritonitis	94, 95, 96
hernias	111, 112
perforated peptic ulcer	53
peptic ulcer bleeding	63
Colostomy	87
Covered perforation	53, 54
Endoscopic retrograde cholangiopancreatography	28, 35,47
Endoscopic ultrasonography	47
Enteroclysis	79
Hematemesis	63
Hernia's strangulation	120
Ileus	89, 97
Inguinal herniorrhaphy	120
Kalo trigonum	32
Kehr point	25
Laparostomy	105
Large bowel obstruction	82, 84

McBurney point	18
Melena	63, 65
Mondor's triad	28, 53
Partial gastrectomy	59
Perforated peptic ulcer	16, 28, 50
Peptic ulcer acute hemorrhage	60
Postcholecystectomy syndrome	35
Pyloroduodenoplasty	59, 74
Repair	
Bassini	123, 125, 132
Girard	128
Kimbarovsky	128
Kukudganov	128
Lichtenstein	129
Martynov	128
Mayo	134, 135
McVay	127
onlay prosthetic	136
Postempsky	128
prosthetic bridging	136
Rudgi-Parlavecho	132
sublay prosthetic	137
Shouldice	125
Spasokukotsky	128
Right-side kidney colic	17, 28
Second-look operations	105
Sing:	
Bartomier	8
Bergmann	64
Blumberg	7, 25, 54
Cullen	42
Delafua	53
Elicer	53
Goby	42
Grey-Turner	42
Grunvald	42
Holsted	42
Kehr	25
Korte	42
Kulenkampff	16,17
Mondor	42
Mayo - Robson	42
Mendel	65
Murphy	25
Mussy	25
Obrazcov	8
Ortner	25

psoas (Roup's)	8
Rozanov	12
Rozdolsky	8
Rovsing	8
Sitkovsky	8
Spizharny	28
ultrasound "target"	14
Voskresensky	7, 42
Simple closure of perforation	58
Small-bowel obstruction	75, 76, 78, 79, 81